CALIFORNIA
TUMOR TISSUE REGISTRY

"TUMORS OF THE LUNG AND MEDIASTINUM"

Study Cases, Subscription B

November 1999

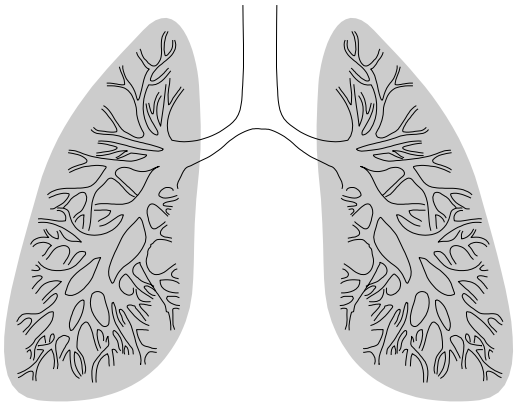

California Tumor Tissue Registry
c/o: Department of Pathology and Human Anatomy
Loma Linda University School of Medicine
11021 Campus Avenue, AH 335
Loma Linda, California 92350
(909) 558-4788
FAX: (909) 558-0188
E-mail: cttr@linkline.com

Target audience:
Practicing pathologists and pathology residents.

Goal:
To acquaint the participant with the histologic features of a variety of benign and malignant neoplasms and tumor-like conditions.

Objectives:
The participant will be able to recognize morphologic features of a variety of benign and malignant neoplasms and tumor-like conditions and relate those processes to pertinent references in the medical literature.

Educational methods and media:
Review of representative glass slides with associated histories.
Feedback on consensus diagnoses from participating pathologists.
Listing of selected references from the medical literature.

Principal faculty:
Weldon K. Bullock, MD
Donald R. Chase, MD

CME Credit:
Loma Linda University School of Medicine designates this continuing medical education activity for up to 2 hours of Category I of the Physician's Recognition Award of the American Medical Association.
CME credit is offered for the subscription year only.

Accreditation:
Loma Linda University School of Medicine is accredited by the Accreditation Council for Continuing Medical Education (ACCME) to sponsor continuing medical education for physicians.

Contributor: Kenneth Frankel, M.D. **Case No. 1 - November 1999**
San Dimas, CA

Tissue from: Lung and pleura **Accession #28464**

Clinical Abstract:

Severe abdominal pain accompanied by shortness of breath and chest pain brought this 39-year-old Caucasian female to the emergency room. A CT scan revealed a large uterine fibroid and chest x-ray showed a 40% pneumothorax. After questioning, she reported another spontaneous pneumothorax 8 months earlier. She was gravida 2, para 2, ab 0 and had had no prior surgeries. A bullectomy and parietal pleurectomy were performed.

Gross Pathology:

The specimens consisted of irregular shaped pieces of membranous, wrinkled, glistening, gray-tan tissue measuring 10.0 cm and 6.0 x 4.0 x 2.5 cm in greatest diameter.

SPECIAL STUDIES:

Actin	positive
CD31	positive
Collagen	positive
Desmin	positive
ER	positive
Pancytokeratin	positive
HMB45	negative

Contributor: Lauren M. Monda, M.D. **Case No. 2 - November 1999**
Santa Barbara, CA

Tissue from: Right lung **Accession #26941**

Clinical Abstract:

During a routine examination, an asymptomatic 4 cm mass was found in the right lung of this 80-year-old female. At surgery, the mass was found to occupy the anterior segment of the right upper lobe. There was no significant hilar or mediastinal lymphadenopathy.

Gross Pathology:

The 130 gram right upper lobe was 13.7 x 8.7 x up to 3.5 cm. A 2.6 cm, intraparenchymal, uniform tan mass produced a puckered pleural surface.

Contributor: Beverly J. Myers, M.D. **Case No. 3 - November 1999**
Sacramento, CA

Tissue from: Mediastinum **Accession #28511**

Clinical Abstract:

After complaining of shortness of breath and fatigue, this 44-year-old female was found to have a large, solid mass in the mediastinum. At surgery, the mass appeared to be originating from the thymus but tracted upward towards the neck. It was adherent to, but not invading, the pericardium.

Gross Pathology:

The 174 gram, smooth surfaced nodular mass was 8.5 x 3.5 x 7.0 cm. The cut surface was whorled pink-tan.

Special Studies (outside facility):

AE1 (keratin)	positive
CK22	positive
CD20-/26	predominantly negative, with positive internal control
CD42/Leu22	positive, small lymphocytes
CD3p	positive, small lymphocytes

Contributor: Pamela Boswell, M.D. **Case No. 4 - November 1999**
San Diego, CA

Tissue from: Right lung and pleura **Accession #28571**

Clinical Abstract:

A 55-year-old retired navy chief complained of chronic cough and nocturnal regurgitation for about a month. A chest x-ray and CT scan revealed a large right pleural effusion and possible atelectasis of the right lower lung field. A right pneumonectomy was performed.

Gross Pathology:

The 750 gram right parietal pleura was 21.0 x 17.0 x 10.0 cm and consisted predominantly of a thick, yellow-gray, firm sheath with a 12 cm diameter remnant of lung parenchyma.

Special Studies (outside facility):

Acid and neutral mucins	negative
34 beta E12 (high MW cytokeratin)	positive
CAM 5.2 (low MW cytokeratin)	positive
EMA	positive
CEA	negative
CD15 (Leu M1)	negative
BER EP4	negative

Electron microscopy: Numerous long, slender, tortuous microvilli along virtually all free cell surfaces. No mucin-filled cytoplasmic vacuoles.

Contributor: Ellen Ko, M.D. **Case No. 5 - November 1999**
Los Angeles, CA

Tissue from: Mediastinum **Accession #28273**

Clinical Abstract:

This 58 year old male was found to have a mediastinal mass.

Gross Pathology:

The 1000 gram specimen consisted of a 17.0 x 11.5 x 9.0 cm lobulated, encapsulated, soft to rubbery mass with a small amount of attached yellow adipose tissue. At one end a 2.5 x 2.0 x 1.3 cm portion of tumor extended through the capsule. The cut surfaces were variegated tan-yellow, hemorrhagic, soft to firm, and lobulated.

Special Studies (outside facility):

Vimentin	negative
CD-34	negative
Desmin	negative
Smooth muscle actin	negative
Keratin	negative
AE1/AE3	negative
S-100	negative

Contributor: J. Michael Young, M.D. **Case No. 6 - November 1999**
Lancaster, PA

Tissue from: Lung **Accession #28433**

Clinical Abstract:

During a work-up for chest pain, this 65-year-old Caucasian male smoker was found to have a left upper lobe lung mass.

Gross Pathology:

The left upper lobe of lung was 19.0 x 11.0 x 4.0 cm and contained a moderately circumscribed tan 6.0 x 4.0 x 3.5 cm nodular mass.

Special Studies (outside facility):

S-100	positive
HMB-45	positive
NK-1	positive
Chromogranin A	negative
Leu-7	negative
Synaptophysin	negative
CD56	negative

Contributor: Philip Gruskin, M.D. **Case No. 7 - November 1999**
Lynwood, CA

Tissue from: Lung **Accession #28257**

Clinical Abstract:

During a coronary artery bypass graft procedure, this 67-year-old female was noted to have a nodule in the upper lobe of her left lung.

Gross Pathology:

The 2.3 x 2.2 x 1.6 cm nodule was tan and slightly lobulated.

Special Studies (outside facility):

Chromogranin	negative
NSE	positive

Contributor: Philip Robinson, M.D. **Case No. 8 - November 1999**
Boynton Beach, FL

Tissue from: Lung **Accession #28555**

Clinical Abstract:

A 55 year old black male smoker presented with hemoptysis. A large mass was found in the lower lobe of his left lung.

Gross Pathology:

The 550 gram left lower lobe was 15 x 11.5 x 6.5 and contained a 7.0 x 7.5 x 5.5 cm necrotic yellow mass.

Special Studies (outside facility):

Keratin	focally positive
S-100	faint staining, possibly artifact
LCA	negative

Contributor: R.L. Lesonsky, M.D. **Case No. 9 - November 1999**
Northridge, CA

Tissue from: Lung **Accession #26812**

Clinical Abstract:

After 6 weeks of cough and fever, this 61-year-old female presented for treatment. A right lower lobe pneumonia and pleural effusion were found. The pneumonia cleared with antibiotics, but a residual 4 cm right lower lobe mass was noted.

Gross Pathology:

The middle and lower lobes of the right lung together were 13 x 12 x 6.5 cm. In the middle lobe was a 5 cm firm area that proved to be an abscess. In the lower lobe was a 1.1 cm diameter gray-white rubbery subpleural nodule.

Contributor: Albert E. Hirst, M.D. **Case No. 10 - November 1999**
Loma Linda, CA

Tissue from: Lung **Accession #26304**

Clinical Abstract:

This 84 year old Hispanic woman was treated for a bacterial pneumonia but the bilateral pulmonary infiltrates did not resolve. Repeated courses of antibiotics and multiple attempts at a tissue diagnosis, including transbronchial and open lung biopsies were unsuccessful. She continued to deteriorate and died one month after initial admission.

Gross Pathology:

At autopsy, the right lung weighed 470 grams, and the left 635 grams. Both had extensively consolidated parenchyma, involving almost the entire lower half of each lung.