CALIFORNIA
TUMOR TISSUE REGISTRY

"TUMORS OF LYMPH NODES & SPLEEN"

Study Cases, Subscription B

March 2001

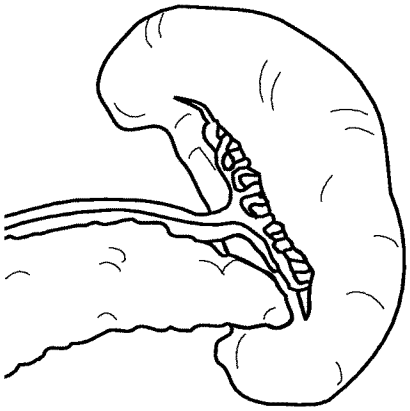

California Tumor Tissue Registry
c/o: Department of Pathology and Human Anatomy
Loma Linda University School of Medicine
11021 Campus Avenue, AH 335
Loma Linda, California 92350
(909) 558-4788
FAX: (909) 558-0188
E-mail: cttr@linkline.com
Case of Month: www.llu.edu/llu/ccct/cotm
Web Page: www.cttr.org

Target audience:
Practicing pathologists and pathology residents.

Goal:
To acquaint the participant with the histologic features of a variety of benign and malignant neoplasms and tumor-like conditions.

Objectives:
The participant will be able to recognize morphologic features of a variety of benign and malignant neoplasms and tumor-like conditions and relate those processes to pertinent references in the medical literature.

Educational methods and media:
Review of representative glass slides with associated histories.
Feedback on consensus diagnoses from participating pathologists.
Listing of selected references from the medical literature.

Principal faculty:
Weldon K. Bullock, MD
Donald R. Chase, MD

CME Credit:
Loma Linda University School of Medicine designates this continuing medical education activity for up to 2 hours of Category I of the Physician's Recognition Award of the American Medical Association.
CME credit is offered for the subscription year only.

Accreditation:
Loma Linda University School of Medicine is accredited by the Accreditation Council for Continuing Medical Education (ACCME) to sponsor continuing medical education for physicians.

Contributor: K. Greg Peterson, M.D. **Case No. 1 - March 2001**
Sioux Falls, SD

Tissue from: Spleen **Accession #28970**

Clinical Abstract:

During work-up for weakness, dyspnea, anemia and fever, this 77-year-old male underwent a CT of chest and abdomen, which showed splenomegaly and lymphadenopathy. A bone marrow biopsy showed no evidence of lymphoma and was interpreted as a possible myeloproliferative disease.

Gross Pathology:

The 1770 gram spleen was 22.0 x 10.0 x 15.0 cm and had a dull, smooth red-brown capsule. The cut surface showed finely nodular parenchyma with prominent white pulp.

SPECIAL STUDIES (Outside Facility):

CD3	negative
CD20	negative
CD23	negative
CD43	positive
CD79	negative

Contributor: Karl G. Peterson, M.D. **Case No. 2 - March 2001**
Sioux Falls, SD

Tissue from: Spleen **Accession #28912**

Clinical Abstract:

This 66-year-old male had abdominal pain. He was found to be severely thrombocytopenic. His white cell count was 38,000 with 88% mature lymphocytes. A splenectomy was performed.

Gross Pathology:

The 1597 gram spleen was 23.5 x 18.0 x 7.5 cm and had a generally homogeneous red parenchyma with scattered white-tan foci up to 0.5 cm in greatest diameter. A 12 gram accessory spleen had a similar appearance.

Contributor: Roger Terry, M.D. **Case No. 3 - March 2001**
Los Angeles, CA

Tissue from: Spleen **Accession #23665**

Clinical Abstract:
After sustaining blunt trauma, this 23-year-old Hispanic male with a known history of leprosy complained of pain in his right shoulder, right ankle and abdomen. A splenectomy was performed.

Gross Pathology:
The 294 gram spleen was 15.0 x 9.0 x 6.0 cm and had multiple capsular lacerations with extensive parenchymal hemorrhage.

Contributor: Howard Otto, M.D. **Case No. 4 - March 2001**
Cheboygan, MI

Tissue from: Right groin **Accession #28711**

Clinical Abstract:
A 37-year-old female presented with an enlarging groin mass.

Gross Pathology:
The 17 gram nodular portion of solid tan-gray tissue was 6.0 x 3.3 x 2.5 cm and had a bulging homogeneous cut surface.

SPECIAL STUDIES (Outside Facility):

CD10	positive
CD20	positive
Bcl-2	positive

Contributor: Philip C. Gordon, M.D. **Case No. 5 - March 2001**
Winter Haven, FL

Tissue from: Spleen **Accession #28973**

Clinical Abstract:
During surgery for acute cholecystitis, a splenectomy was also performed on this 76-year old male. There was no concurrent lymphadenopathy.

Gross Pathology:
The spleen weighed 375 grams and contained a solitary 7.3 cm fleshy mass.

SPECIAL STUDIES (Outside Facility):

Bcl-2	positive
CD3	negative
CD20	positive
CD43	positive

Contributor: John Craig, M.D. **Case No. 6 - March 2001**
Pasadena, CA

Tissue from: Left axilla **Accession #24394**

Clinical Abstract:
This 14-year-old male complained of a left axillary mass, which was excised.

Gross Pathology:
The 9 gram, soft spongy, well encapsulated tan-white mass measured 3.0 x 2.5 x 2.0 cm and had a moist, light tan uniform cut surface.

Contributor: Philip Robinson, M.D. **Case No. 7 - March 2001**
Boynton Beach, FL

Tissue from: Left groin **Accession #28840**

Clinical Abstract:
This 51-year-old male developed painful swelling in the left groin, originally interpreted as cellulitis.

Gross Pathology:
A 14.3 x 6.5 x 3.5 cm aggregate consisted of multiple gray, pale tan and white tissue fragments.

SPECIAL STAINS:

CD3	negative
CD30	positive
CD43	positive

Contributor: LLUMC Pathology Group (jdc) **Case No. 8 - March 2001**
Loma Linda, CA

Tissue from: Cervical lymph node **Accession #27620**

Clinical Abstract:
Bilateral cervical lymphadenopathy led to a lymph node biopsy from this 10-year-old male.

Gross Pathology:
The 2.5 gram white-tan nodule was 3.0 x 2.5 x 1.5 cm.

SPECIAL STAINS:

CD30	positive
CD15	positive
CD45RO	negative
CD20	negative
EMA	negative

Contributor: Harvey Upham, M.D. **Case No. 9 - March 2001**
Whittier, CA

Tissue from: Left cervical lymph node **Accession #17680**

Clinical Abstract:

The parents of this 6-year-old male noticed a non-painful lump on the left side of his neck. He was brought for work-up when several nodules appeared adjacent to it.

Gross Pathology:

The 13 pink to tan lymph nodes varied in size from 0.8 cm to 2.9 cm in diameter. Their cut surfaces were moist, uniform tan and slightly bulging.

Contributor: Gerald Dalgleish, M.D. **Case No. 10 - March 2001**
Simi Valley, CA

Tissue from: Urinary bladder **Accession #28676**

Clinical Abstract:

When physical exam disclosed an enlarged hard prostate, this 58-year-old male underwent work-up which included a renal ultrasound. This showed an atrophic left kidney with severe hydronephrosis. CT scan showed a large mass involving the trigone of the bladder, prostate and seminal vesicles and extending to level of the iliac crest. A transurethral resection of the bladder mass was performed. Subsequently, the atrophic kidney was removed and the distal ureter found to be involved by the same process.

Gross Pathology:

Not available.

SPECIAL STUDIES (Outside Facility):

S-100 strongly positive