CALIFORNIA
TUMOR TISSUE REGISTRY

GENERAL PATHOLOGY

Minutes – Subscription A

March, 2007

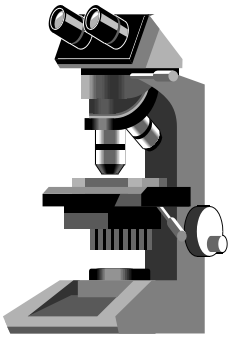

SUGGESTED READING (General Topics from Recent Literature):

Gardner Fibroma. A Clinicopathologic and Immunohistochemical Analysis of 45 Patients with 57 Fibromas. Coffin CM, Hornick JL, et al. *Am J Surg Pathol* 2007; 31:410-416.

Extent of Low-Grade Dysplasia Is a Risk Factor for the Development of Esophageal Adenocarcinoma in Barrett's Esophagus. Srivastava A, Hornick JL, et al. *Am J Gastroenterol* 2007; 102:483-493.

Mitotic Rate in Melanoma. A Reexamination. Attis MN and Vollmer RT. *Am J Clin Pathol* 2007; 127:380-384.

Nonalcoholic Fatty Liver Disease in Severely Obese Subjects. Gholam PM, Flancbaum L, et al. *Am J Gastroenterol* 2007; 102:399-408.

Cliniical and Endoscopic Factors Predict Higher Pathologic Grades of Barrett Dysplasia. Anandasabapathy S, Jhamb J, et al. *Cancer* 2007; 109:668-674.

Distribution of HPV Genotypes in 282 Women with Cervical Lesions Evidence for Three Categories of Intraepithelial Lesions Based on Morphology and HPV Type. Zuna RE, Allen RA, et al. *Mod Pathol* 2007; 20:167-174.

California Tumor Tissue Registry
c/o: Department of Pathology and Human Anatomy
Loma Linda University School of Medicine
11021 Campus Avenue, AH 335
Loma Linda, California 92350
(909) 558-4788
FAX: (909) 558-0188
E-mail: cttr@linkline.com
Web site & Case of the Month: www.cttr.org

FILE DIAGNOSES

(Preferably submitted on website at www.cttr.org. Click "subscriptions", then submit answers".)

CTTR Subscription A March, 2007

Case 1:

Cardiac/atrial myxoma

T-32120, M-88400

Case 2:

Renal cell carcinoma, clear cell, kidney

T-71000, M-83123

Case 3:

Pleomorphic adenoma, parotid

T-22300, M-89400

Case 4:

Sertoli-Leydig cell tumor, ovary

T-86922, M-86310

Case 5:

Phyllodes tumor, histologically benign, breast

T-04000, M-90213

Case 6:

Histiocytic necrotizing lymphadenitis (Kikuchi-Fujimoto disease). Cannot rule out T-cell lymphoma.

T-08000, M-40000

Case 7:

Inflammatory myofibroblastic tumor, lung

T-28000, M-03090

Case 8:

Mesenteric fibromatosis (CD117-positive)

T-Y4100, M-76100

Case 9:

Schwannoma, mediastinum

T-Y2300, M-95600

Case 10:

Chordoma, sacrococcygeal ("retro-rectal")

T-Y2300, M-95600

Baldwin Park (Kaiser Permanente) - Atrial myxoma (2)
Claremont - Atrial myxoma
Clovis - Atrial myxoma
Glendale - Atrial myxoma
Granada Hills - Atrial myxoma
Long Beach (Long Beach Veterans Group) - Atrial myxoma (2)
Monterey (Community Hospital of Monterey Peninsula) - Cardiac myxoma
Monterey Park (Garfield Medical Center) - Myxoid angiosarcoma
Oakland - Myxoma
Oakland (Alameda County Medical Center) - Atrial myxoma
Orange (Kaiser Permanente) - Cardiac myxoma
Oxnard (St. John's Regional Medical Center) - Atrial myxoma (5)
Sacramento (UC Davis Residents) - Atrial myxoma
San Diego - Cardiac myxoma
San Diego (Naval Medical Center) - Myxoma
San Diego (UCSD) - Atrial myxoma (2)
San Francisco (SF General Hospital) - Atrial myxoma
Santa Barbara - Cardiac myxoma
Santa Rosa (Santa Rosa Memorial Hospital) - Cardiac myxoma/atrial myxoma (3)
Sonoma (Sonoma Valley Hospital) - Cardiac myxoma
Woodland Hill - Myxoma
Woodland Hills (Suda's Soldiers) - Myxoma
Alabama (Baptist Medical Center) - Cardiac myxoma
Colorado, Ft Collins - Atrial myxoma
Florida (Baptist Hospital) - Myxoma (4)
Florida (Munroe Regional Medical Center) - Atrial myxoma
Georgia, Decatur - Cardiac myxoma
Illinois, Burr Ridge - Cardiac myxoma/atrial myxoma
Illinois (Loyola University of Chicago) - Myxoma
Indiana (Howard Regional Medical Center) - Cardiac myxoma
Iowa (Winneshiek Medical Center) - Organizing thrombus
Kansas (Cytocheck Lab) - Myxoma (2)
Kentucky (University of Louisville) - Cardiac myxoma
Louisiana (Louisiana State University Medical Center) - Myxoma
Massachusetts (Berkshire Medical Center) - Atrial myxoma
Massachusetts (Beverly Hospital) - Cardiac myxoma
Massachusetts, Peabody - Atrial myxoma, heart
Massachusetts (Tufts New England Medical Center) - Atrial myxoma
Michigan (Oakwood Hospital) - Cardiac myxoma
Montana, Missoula - Atrial myxoma
Nebraska (Creighton University) - Atrial myxoma
New Mexico, Albuquerque - Atrial myxoma
New York (Long Island Jewish Medical Center) - Atrial myxoma
New York (Nassau University Medical Center) - Atrial myxoma
New York (Stony Brook University Hospital Residents) - Cardiac myxoma
New York (SUNY Downstate Medical Center) - Atrial myxoma
North Carolina (Mountain Area Pathology) - Atrial myxoma (3)
Ohio (Northside Hospital) - Cardiac myxoma
Oklahoma, Tulsa - Atrial myxoma
Pennsylvania (Conemaugh Memorial Medical Center) - Atrial myxoma
Pennsylvania (Drexel University College of Medicine) - Atrial myxoma
Pennsylvania (Lehigh Valley Hospital) - Atrial myxoma
Pennsylvania (Magee Women's Hospital) - Cardiac myxoma
Pennsylvania (Mt Nittany Medical Center) - Myxoma, rt atrium
Pennsylvania (Pennsylvania Hospital Residents) - Atrial myxoma
Tennessee, Kingsport - Cardiac myxoma
Texas, Crystal Beach - Cardiac myxoma
Texas, Houston - Atrial myxoma
Texas, Lubbock - Myxoma
Texas, Sugarland - Cardiac myxoma
Washington (Madigan Army Medical Center) - Atrial myxoma (12)

Washington (Seattle Veterans Medical Center) - Myxoma
West Virginia (Greenbrier Valley Medical Center) - Thrombi organized
Australia (Royal Hobart Hospital) - Atrial myxoma
Australia (Royal Prince Alfred Hospital) - Cardiac myxoma
Australia (Sullivan Nicolaides Pathology - Cardiac myxoma, rt atrium
Canada, Saskatoon - Cardiac myxoma
Canada (University Hospital of Sherbrooke) - Cardiac myxoma
Germany, Hamburg - Myxoma
Ireland (Galway Residents) - Atrial myxoma
Ireland (Kerry General Hospital) - Atrial myxoma
Japan (Asashi General Hospital) - Cardiac myxoma
Japan (Kyoto University Hospital) - Cardiac myxoma
Netherlands, Amstelveen - Cardiac myxoma
Qatar (Hamad Medical Corporation) - Atrial myxoma
United Kingdom (John Radcliffe Hospital) - Atrial myxoma

Case 1 - Diagnosis:

Cardiac/atrial myxoma
T-32120, M-88400

Case 1 – References:

Gammie JS, Abrishamchian AR and Griffith BP. Cardiac Autotransplantation and Radical Bi-Atrial Resection for Recurrent Atrial Myxoma. *Ann Thorac Surg* 2007; 83(4):1545-1547.
Gismondi RA, Kaufman R, Correa GA, et al. Left Atrial Myxoma Associated with Obstructive Coronary Artery Disease. *Arq Bras Cardiol* 2007; 88(1):e-1-3.
Fujisaki K, Shohno Y, Yoshida T, et al. Acute Renal Infarction in a Patient with Left Atrial Myxoma. *Clin Nephrol* 2007; 67(1):53-57.
Kucukarslan N, Kirilmaz A, Ulusoy E, et al. Eleven-Year Experience in Diagnosis and Surgical Therapy of Right Atrial Masses. *J Card Surg* 2007; 22(1):39-42.

Case No. 2, Accession No. 30030 March 2007 A

Baldwin Park (Kaiser Permanente) - Renal cell carcinoma, clear cell type (3)
Claremont - Renal cell carcinoma
Clovis - Kidney, renal cell carcinoma (clear cell)
Glendale - Renal cell carcinoma, clear cell type
Granada Hills - Renal clear cell carcinoma
Long Beach (Long Beach Veterans Group) - Renal cell carcinoma (2)
Monterey (Community Hospital of Monterey Peninsula) - Clear cell renal cell carcinoma
Monterey Park (Garfield Medical Center) - Renal clear cell carcinoma
Oakland - Renal cell carcinoma, clear cell type
Oakland (Alameda County Medical Center) - Renal cell carcinoma
Orange (Kaiser Permanente) - Renal cell carcinoma, clear cell type, grade 2
Oxnard (St. John's Regional Medical Center) - Renal cell carcinoma, clear cell type (5)
Sacramento (UC Davis Residents) - Renal cell carcinoma, conventional type, grade 1
San Diego - Clear cell carcinoma, kidney
San Diego (Naval Medical Center) - Clear cell renal cell carcinoma
San Diego (UCSD) - Renal cell carcinoma, clear cell, Fuhrman 2 (2)
San Francisco (SF General Hospital) - Renal cell carcinoma, clear cell type
Santa Barbara - Renal cell carcinoma
Santa Rosa (Santa Rosa Memorial Hospital) - Renal cell carcinoma, clear cell type (3)
Sonoma (Sonoma Valley Hospital) - Renal cell carcinoma, clear cell type
Woodland Hills - Renal cell carcinoma, clear cell type
Woodland Hills (Suda's Soldiers) - Renal cell carcinoma (clear cell type)
Alabama (Baptist Medical Center) - Renal cell carcinoma, clear cell type
Colorado, Ft Collins - Renal cell carcinoma, clear cell type, Fuhrman, grade 1
Florida (Baptist Hospital) - Renal cell carcinoma, clear cell type (4)
Florida (Munroe Regional Medical Center) - Renal cell carcinoma, clear cell type
Georgia, Decatur - Renal cell carcinoma, conventional type
Illinois, Burr Ridge - Conventional clear cell carcinoma (1); Kidney clear cell carcinoma, grade 1 to 2 (2)
Illinois (Loyola University of Chicago) - Clear cell renal cell carcinoma

Indiana (Howard Regional Medical Center) - Clear cell carcinoma
Iowa (Winneshiek Medical Center) - Clear cell renal carcinoma
Kansas (Cytocheck Lab) - Renal cell carcinoma, clear cell (2)
Kentucky (University of Louisville) - Renal cell carcinoma, clear cell type
Louisiana (Louisiana State University Medical Center) - Renal cell carcinoma
Massachusetts (Berkshire Medical Center) - Clear cell carcinoma (conventional renal cell carcinoma)
Massachusetts (Beverly Hospital) - Clear cell renal cell carcinoma, grade 1/4
Massachusetts, Peabody - Renal cell carcinoma, clear cell type
Massachusetts (Tufts New England Medical Center) - Clear cell renal cell carcinoma
Michigan (Oakwood Hospital) - Clear cell renal cell carcinoma
Montana, Missoula - Clear cell renal cell carcinoma
Nebraska (Creighton University) - Clear cell renal cell carcinoma
New Mexico, Albuquerque - Renal cell carcinoma, clear cell type
New York (Long Island Jewish Medical Center) - Renal cell carcinoma
New York (Nassau University Medical Center) - Renal cell carcinoma, clear cell
New York (Stony Brook University Hospital Residents) - Renal cell carcinoma, clear cell, grade 1
New York (SUNY Downstate Medical Center) - Renal clear cell carcinoma, low grade
North Carolina (Mountain Area Pathology) - Clear cell renal carcinoma (3)
Ohio (Northside Hospital) - Clear cell carcinoma
Oklahoma, Tulsa - Renal cell carcinoma, clear cell type
Pennsylvania (Conemaugh Memorial Medical Center) - Renal cell carcinoma, clear cell type
Pennsylvania (Drexel University College of Medicine) - Renal cell carcinoma, Fuhrman, Grade 2
Pennsylvania (Lehigh Valley Hospital) - All of clear cell type
Pennsylvania (Magee Women's Hospital) - Clear cell carcinoma of the kidney
Pennsylvania (Mt Nittany Medical Center) - Renal cell carcinoma, clear cell type, grade I-II/IV
Pennsylvania (Pennsylvania Hospital Residents) - Clear cell carcinoma
Tennessee, Kingsport - Renal carcinoma, clear cell type
Texas, Crystal Beach - Clear cell carcinoma
Texas, Houston - Renal cell carcinoma, clear cell type
Texas, Lubbock - Renal cell carcinoma, clear cell type
Texas, Sugarland - Clear cell renal cell carcinoma
Washington (Madigan Army Medical Center) - Renal cell carcinoma, clear cell type (12)
Washington (Seattle Veterans Medical Center) - Renal cell carcinoma, low grade clear cell growth pattern
West Virginia (Greenbrier Valley Medical Center) - Hypernephroma
Australia (Royal Hobart Hospital) - Clear cell renal cell carcinoma, grade 1
Australia (Royal Prince Alfred Hospital) - Clear cell renal cell carcinoma, Fuhrman, grade 2
Australia (Sullivan Nicolaides Pathology) - Renal cell carcinoma, clear cell type, Fuhrman, grade 2
Canada, Saskatoon - Conventional (clear cell) renal cell carcinoma
Canada (University Hospital of Sherbrooke) - Kidney clear cell carcinoma
Germany, Hamburg - Renal clear cell carcinoma
Ireland (Galway Residents) - Clear cell (conventional) renal cell carcinoma
Ireland (Kerry General Hospital) - Renal cell carcinoma
Japan (Asashi General Hospital) - Clear cell renal cell carcinoma
Japan (Kyoto University Hospital) - Clear cell renal cell carcinoma
Netherlands, Amstelveen - Clear cell adenocarcinoma of the kidney
Qatar (Hamad Medical Corporation) - Conventional renal cell carcinoma
United Kingdom (John Radcliffe Hospital) - Clear cell carcinoma kidney, Fuhrman, grade 2

Case 2 - Diagnosis:

Renal cell carcinoma, clear cell, kidney
T-71000, M-83123

Case 2 - References:

Lam JS, Breda A, Belldegrun AS, et al. Evolving Principles of Surgical Management and Prognostic Factors for Outcome in Renal Cell Carcinoma. *J Clin Oncol* 2006; 24(35):5565-5575.
Dimashkieh HH, Lohse CM, Blute ML, et al. Extranodal Extension in Regional Lymph nodes is Associated With Outcome in Patients With Renal Cell Carcinoma. *J Urol* 2006; 176(5):1978-1982.
Kuhn E, De Anda J, Manoni S, et al. Renal Cell Carcinoma Associated With Prominent Angioleiomyoma-Like Proliferation. Report of 5 Cases and Review of the Literature. *Am J Surg Pathol* 2006; 30(11):1372-1381.
Kutikov A, Fossett LK, Ramchandani P, et al. Incidence of Benign Pathologic Findings at Partial Nephrectomy For Solitary Renal Mass Presumed to be Renal Cell Carcinoma on Preoperative Imaging. *Urol* 2006; 68(4):737-740.
Shuch BM, Lam JS, Belldegrun AS, et al. Prognostic Factors in Renal Cell Carcinoma. *Semin Oncol* 2006; 33(5):563-575.

Baldwin Park (Kaiser Permanente) - Pleomorphic adenoma (3)
Claremont - Pleomorphic adenoma
Clovis - Pleomorphic adenoma, parotid
Glendale - Pleomorphic adenoma
Granada Hills - Papillary carcinoma with metaplastic features
Long Beach (Long Beach Veterans Group) - Pleomorphic adenoma (1); Benign mixed tumor of parotid (1)
Monterey (Community Hospital of Monterey Peninsula) - Pleomorphic adenoma
Monterey Park (Garfield Medical Center) - Pleomorphic adenoma (benign)
Oakland - Mixed tumor
Oakland (Alameda County Medical Center) - Pleomorphic adenoma
Orange (Kaiser Permanente) - Pleomorphic adenoma
Oxnard (St. John's Regional Medical Center) - Pleomorphic adenoma/ mixed tumor (5)
Sacramento (UC Davis Residents) - Pleomorphic adenoma
San Diego - Pleomorphic adenoma, parotid gland
San Diego (Naval Medical Center) - Pleomorphic adenoma
San Diego (UCSD) - Pleomorphic adenoma (2)
San Francisco (SF General Hospital) - Pleomorphic adenoma
Santa Barbara - Pleomorphic adenoma
Santa Rosa (Santa Rosa Memorial Hospital) - Pleomorphic adenoma (mixed tumor) (3)
Sonoma (Sonoma Valley Hospital) - Benign mixed tumor (pleomorphic adenoma)
Woodland Hills - Pleomorphic adenoma
Woodland Hills (Suda's Soldiers) - Pleomorphic adenoma (benign mixed tumor)
Alabama (Baptist Medical Center) - Pleomorphic adenoma
Colorado, Ft Collins - Benign mixed tumor
Florida (Baptist Hospital) - Pleomorphic adenoma/mixed tumor (4)
Florida (Munroe Regional Medical Center) - Pleomorphic adenoma
Georgia, Decatur - Pleomorphic adenoma
Illinois, Burr Ridge - Pleomorphic adenoma/mixed (2)
Illinois (Loyola University of Chicago) - Pleomorphic adenoma
Indiana (Howard Regional Medical Center) - Pleomorphic adenoma
Iowa (Winneshiek Medical Center) - Mixed tumor
Kansas (Cytocheck Lab) - Mixed tumor/pleomorphic adenoma (2)
Kentucky (University of Louisville) - Pleomorphic adenoma
Louisiana (Louisiana State University Medical Center) - Pleomorphic adenoma
Massachusetts (Berkshire Medical Center) - Pleomorphic adenoma (mixed tumor)
Massachusetts (Beverly Hospital) - Pleomorphic adenoma
Massachusetts, Peabody - Pleomorphic adenoma, parotid gland
Massachusetts (Tufts New England Medical Center) - Pleomorphic adenoma
Michigan (Oakwood Hospital) - Pleomorphic adenoma
Montana, Missoula - Pleomorphic adenoma
Nebraska (Creighton University) - Pleomorphic adenoma
New Mexico, Albuquerque – Pleomorphic adenoma
New York (Long Island Jewish Medical Center) - Pleomorphic adenoma
New York (Nassau University Medical Center) - Pleomorphic adenoma
New York (Stony Brook University Hospital Residents) - Pleomorphic adenoma
New York (SUNY Downstate Medical Center) - Pleomorphic adenoma
North Carolina (Mountain Area Pathology) - Pleomorphic adenoma (3)
Ohio (Northside Hospital) - Pleomorphic adenoma
Oklahoma, Tulsa - Mixed tumor (pleomorphic adenoma)
Pennsylvania (Conemaugh Memorial Medical Center - Benign mixed tumor
Pennsylvania (Drexel University College of Medicine) - Pleomorphic adenoma
Pennsylvania (Lehigh Valley Hospital) - Pleomorphic adenoma
Pennsylvania (Magee Women's Hospital) - Pleomorphic adenoma
Pennsylvania (Mt Nittany Medical Center) - Mixed tumor with chondroid and osseous differentiation, left parotid gland
Pennsylvania (Pennsylvania Hospital Residents) - Benign mixed tumor/pleomorphic adenoma
Tennessee, Kingsport - Pleomorphic adenoma with bone formation
Texas, Crystal Beach - Cellular mixed tumor
Texas, Houston - Pleomorphic adenoma
Texas, Lubbock - Cellular pleomorphic adenoma
Texas, Sugarland - Pleomorphic adenoma
Washington (Madigan Army Medical Center) - Pleomorphic adenoma (12)

Washington (Seattle Veterans Medical Center) - Pleomorphic adenoma
West Virginia (Greenbrier Valley Medical Center) - Mixed tumor (pleomorphic adenoma)
Australia (Royal Hobart Hospital) - Pleomorphic adenoma with prominent chondro-osseous metaplasia
Australia (Royal Prince Alfred Hospital) - Pleomorphic adenoma
Australia (Sullivan Nicolaides Pathology) - Pleomorphic adenoma, parotid gland
Canada, Saskatoon - Pleomorphic adenoma
Canada (University Hospital of Sherbrooke) - Pleomorphic adenoma of the parotid gland
Germany, Hamburg - Pleomorphic adenoma
Ireland (Galway Residents) – Pleomorphic adenoma/benign mixed tumor
Ireland (Kerry General Hospital) - Pleomorphic salivary adenoma
Japan (Asashi General Hospital) - Pleomorphic adenoma
Japan (Kyoto University Hospital) - Pleomorphic adenoma
Netherlands, Amstelveen - Pleomorphic adenoma of the parotid gland
Qatar (Hamad Medical Corporation) - Pleomorphic adenoma
United Kingdom (John Radcliffe Hospital) - Pleomorphic adenoma, parotid

Case 3 - Diagnosis:

Pleomorphic adenoma, parotid
T-22300, M-89400

Case 3 - References:

Parwani AV, Lujan G and Ali SZ. Myoepithelial Carcinoma Arising in a Pleomorphic Adenoma of the Parotid Gland. Report of a Case With Cytopathologic Findings. *Acta Cytol* 2006; 50(1):93-96.

Das DK, Petkar MA, Al-Mane NM, et al. Role of Fine Needle Aspiration Cytology in the Diagnosis of Swellings in the Salivary Gland Regions. A Study of 712 Cases. *Med Princ Pract* 2004; 13(2):95-106.

Cajulis RS, Gokaslan ST, Yu GH, et al. Fine Needle Aspiration Biopsy of the Salivary Glands. A Five-Year Experience With Emphasis on Diagnostic Pitfalls. *Acta Cytol* 1997; 41(5):1412-1420.

Layfield LJ, Reznicek M, Lowe M, et al. Spontaneous Infarction of a Parotid Gland Pleomorphic Adenoma. Report of a Case with Cytologic and Radiographic Overlap with a Primary Salivary Gland Malignancy. *Acta Cytol* 1992; 36(3):381-386.

Pitman MB, Thor AD, Goodman ML, et al. Benign Metastasizing Pleomorphic Adenoma of Salivary Gland. Diagnosis of Bone Lesions by Fine-Needle Aspiration Biopsy. *Diagn Cytopathol* 1992; 8(4):384-387.

Case No. 4, Accession No. 30172 March 2007 A

Baldwin Park (Kaiser Permanente) - Probable metastatic breast carcinoma (1); Thecoma (2)
Claremont - Clear cell carcinoma
Clovis - Ovary, sex cord stroma (Sertoli Leydig)
Glendale - Sertoli-Leydig cell tumor
Granada Hills - Sertoli cell tumor
Long Beach (Long Beach Veterans Group) - Sex cord tumor, favor Sertoli cell tumor (2)
Monterey (Community Hospital of Monterey Peninsula) - Metastatic carcinoma, favor breast
Monterey Park (Garfield Medical Center) - Adrenal cortical carcinoma
Oakland - Clear cell carcinoma
Oakland (Alameda County Medical Center) - Sex cord stromal tumor
Orange (Kaiser Permanente) - Sertoli-Leydig cell tumor
Oxnard (St. John's Regional Medical Center) - Sertoli cell tumor (4); Adrenal carcinoma (1)
Sacramento (UC Davis Residents) - Sertoli-Leydig cell tumor
San Diego - Sertoli cell tumor, ovary
San Diego (Naval Medical Center) - Sertoli cell tumor
San Diego (UCSD) - Adenocarcinoma, primary vs. metastatic (2)
San Francisco (SF General Hospital) - Sertoli-Leydig cell tumor
Santa Barbara - Sclerosing stromal tumor
Santa Rosa (Santa Rosa Memorial Hospital) - Sertoli-Leydig tumor (2); Malignant neoplasm, probable poorly differentiated sex cord stromal tumor (1)
Sonoma (Sonoma Valley Hospital) - Sertoli-Leydig cell tumor
Woodland Hills - Granulosa cell tumor
Woodland Hills (Suda's Soldiers) - Sertoli-Ledig cell tumor/lipid rich)
Alabama (Baptist Medical Center) - Metastatic breast carcinoma, ovary
Colorado, Ft Collins - Adrenocortical hyperplasia vs. adenoma
Florida (Baptist Hospital) - Sertoli-Leydig cell tumor (3); Steroid tumor (1)

Florida (Munroe Regional Medical Center) - Granulosa cell tumor
Georgia, Decatur - Steroid cell tumor, NOS
Illinois, Burr Ridge - Clear cell carcinoma (1); Sertoli cell tumor, ovary (1)
Illinois (Loyola University of Chicago) - Sertoli cell tumor
Indiana (Howard Regional Medical Center) - Granulosa cell tumor
Iowa (Winneshiek Medical Center) - Clear cell carcinoma
Kansas (Cytocheck Lab) - Adrenal cortical tumor (1); Sex cord/stroma tumor, NOS (1)
Kentucky (University of Louisville) - Sertoli cell tumor
Louisiana (Louisiana State University Medical Center) - Sex cord (Sertoli) tumor
Massachusetts (Berkshire Medical Center) - Sertoli cell tumor
Massachusetts (Beverly Hospital) - Sex cord tumor/Sertoli cell tumor
Massachusetts, Peabody - Sex cord tumor with annular tubules, ovary
Massachusetts (Tufts New England Medical Center) - Sertoli cell tumor
Michigan (Oakwood Hospital) - Sertoli cell tumor vs. metastatic carcinoma
Montana, Missoula - Sertoli cell tumor
Nebraska (Creighton University) - Mixed germ cell tumor
New Mexico, Albuquerque - Sertoli cell tumor
New York (Long Island Jewish Medical Center) - Sertoli tumor
New York (Nassau University Medical Center) - Sertoli cell tumor
New York (Stony Brook University Hospital Residents) - Sertoli cell tumor
New York (SUNY Downstate Medical Center) - Sertoli cell tumor
North Carolina (Mountain Area Pathology) - Sertoli cell tumor (3)
Ohio (Northside Hospital) - Sertoli-Leydig cell tumor
Oklahoma, Tulsa - Sex cord stromal favor sertoli cell tumor
Pennsylvania (Conemaugh Memorial Medical Center) - Sertoli-Leydig cell tumor
Pennsylvania (Drexel University College of Medicine) - Lipid-rich sertoli cell tumor
Pennsylvania (Lehigh Valley Hospital) - Adenocarcinoma favor metastatic
Pennsylvania (Magee Women's Hospital) - Sertoli cell tumor
Pennsylvania (Mt Nittany Medical Center) - Steroid cell tumor, lt ovary
Pennsylvania (Pennsylvania Hospital Residents) - Sertoli cell, lipid-rich variant
Tennessee, Kingsport - Adult granulosa cell tumor
Texas, Crystal Beach - Sertoli-Leydig cell tumor or other (sex cord etc.)
Texas, Houston - Sertoli cell tumor, lipid-rich
Texas, Lubbock - Sertoli cell tumor
Texas, Sugarland - Sertoli cell tumor, lipid-rich variant
Washington (Madigan Army Medical Center) - Sertoli cell tumor (11); Sclerosing stromal tumor (1)
Washington (Seattle Veterans Medical Center) - Sex cord stromal tumor
West Virginia (Greenbrier Valley Medical Center) - Adenocarcinoma
Australia (Royal Hobart Hospital) - Sertoli-Leydig cell tumour
Australia (Royal Prince Alfred Hospital) - Sertoli-Leydig tumour
Australia (Sullivan Nicolaides Pathology) - Metastatic breast carcinoma, ovary
Canada, Saskatoon - Clear cell carcinoma of ovary
Canada (University Hospital of Sherbrooke) - Sex cord tumor (Sertoli-Leydig)
Germany, Hamburg - Sertoli-Leydig cell tumor
Ireland (Galway Residents) - Sertoli cel tumor, lipid-rich
Ireland (Kerry General Hospital) - Sertoli cell tumour
Japan (Asashi General Hospital) - Sertoli-Leydig cell tumor
Japan (Kyoto University Hospital) - Metastatic carcinoma with stromal reaction and luteinization, most likely
Netherlands, Amstelveen - Sertoli-Leydig cell tumor, intermediately differentiation
Qatar (Hamad Medical Corporation) - Sertoli-Leydig cell tumor
United Kingdom (John Radcliffe Hospital) - Thecoma

Case 4 - Diagnosis:

Sertoli-Leydig cell tumor, ovary
T-86922, M-86310

Case 4 - References:

Grove A and Vestergaard V. Ovarian Sertoli-Leydig Cell Tumor of Intermediate Grade With Heterologous Elements of Rhabdomyosarcoma. A Case Report and a Review of the Literature. *Ann Diagn Pathol* 2006; 10(5):288-293.
Choong CS, Fuller PJ, Chu S, et al. Sertoli-Leydig Cell Tumor of the Ovary, A Rare Cause of Precocious Puberty in a 12-Month-Old Infant. *J Clin Endocrinol Metab* 202; 87(1):49-56.
Lantzsch T, Stoerer S, Lawrenz K, et al. Sertoli-Leydig Cell Tumor. *Arch Gynecol Obstet* 2001; 264 (4):206-208.

Gordon MD, Corless C, Renshaw AA, et al. CD99, Keratin, and Vimentin Staining of Sex Cord-Stromal Tumors, Normal Ovary, and Testis. *Mod Pathol* 1998; 11(8):769-773.
Stewart CJ, Jeffers MD and Kennedy A. Diagnostic Value of Inhibin Immunoreactivity in Ovarian Gonadal Stromal Tumours and Their Histological Mimics. *Histopathol* 1997; 31(1):67-74.

Case No. 5, Accession No. 29964 March 2007 A

Baldwin Park (Kaiser Permanente) - Phyllodes tumor (5)
Claremont - Benign Phyllodes tumor
Clovis - Phyllodes tumor, breast (high grade)
Glendale - Low-grade Phyllodes tumor
Granada Hills - Benign Phyllodes tumor
Long Beach (Long Beach Veterans Group) - Phyllodes tumor, low malignant potential
Monterey (Community Hospital of Monterey Peninsula) - Benign Phyllodes tumor
Monterey Park (Garfield Medical Center) - Benign Phyllodes tumor
Oakland - Phyllodes tumor
Oakland (Alameda County Medical Center) - Benign Phyllodes tumor
Orange (Kaiser Permanente) - Phyllodes tumor, low grade
Oxnard (St. John's Regional Medical Center) - Phyllodes tumor (5)
Sacramento (UC Davis Residents) - Phyllodes tumor
San Diego - Phyllodes tumor, benign, breast
San Diego (Naval Medical Center) - Phyllodes tumor
San Diego (UCSD) - Low grade Phyllodes tumor (2)
San Francisco (SF General Hospital) - Phyllodes tumor
Santa Barbara - Phyllodes tumor
Santa Rosa (Santa Rosa Memorial Hospital) - Benign Phyllodes tumor (3)
Sonoma (Sonoma Valley Hospital) - Phyllodes tumor
Woodland Hills - Phyllodes tumor, benign
Woodland Hills (Suda's Soldiers) - Phyllodes tumor
Alabama (Baptist Medical Center) - Phyllodes tumor, intermediate grade
Colorado, Ft Collins - Low grade Phyllodes tumor
Florida (Baptist Hospital) - Phyllodes tumor (4)
Florida (Munroe Regional Medical Center) – Phyllodes tumor
Georgia, Decatur - Low grade Phyllodes tumor
Illinois, Burr Ridge - Phyllodes tumor (2)
Illinois (Loyola University of Chicago) - Phyllodes
Indiana (Howard Regional Medical Center) - Phyllodes tumor
Iowa (Winneshiek Medical Center) - Phyllodes tumor
Kansas (Cytocheck Lab) - Fibroadenoma (1); Phyllodes tumor, low grade (1)
Kentucky (University of Louisville) - Benign Phyllodes tumor
Louisiana (Louisiana State University Medical Center) - Phyllodes tumor
Massachusetts (Berkshire Medical Center) - Phyllodes tumor
Massachusetts (Beverly Hospital) - Benign Phyllodes tumor
Massachusetts, Peabody - Phyllodes tumor, breast
Massachusetts (Tufts New England Medical Center) - Benign Phyllodes tumor
Michigan (Oakwood Hospital) - Phyllodes tumor
Montana, Missoula - Phyllodes tumor
Nebraska (Creighton University) - Phyllodes tumor
New Mexico, Albuquerque - Phyllodey tumor
New York (Long Island Jewish Medical Center) - Benign Phyllodes tumor
New York (Nassau University Medical Center) - Phyllodes tumor, benign
New York (Stony Brook University Hospital Residents) - Phyllodes tumor, borderline
New York (SUNY Downstate Medical Center) - Phyllodes tumor
North Carolina (Mountain Area Pathology) - Phyllodes tumor (3)
Ohio (Northside Hospital) – Borderline Phyllodes tumor
Oklahoma, Tulsa – Phyllodes tumor, benign
Pennsylvania (Conemaugh Memorial Medical Center) - Phyllodes tumor
Pennsylvania (Drexel University College of Medicine) - Phyllodes tumor
Pennsylvania (Lehigh Valley Hospital) - Phyllode tumor
Pennsylvania (Magee Women's Hospital) - Benign Phyllodes tumor
Pennsylvania (Mt Nittany Medical Center) - Low grade Phyllodes tumor, lt breast
Pennsylvania (Pennsylvania Hospital Residents) - Phyllodes tumor

Tennessee, Kingsport - Phyllodes tumor, low grade
Texas, Crystal Beach - Phyllodes tumor
Texas, Houston - Benign phyllodes tumor
Texas, Lubbock - Phyllodes tumor, benign
Texas, Sugarland - Phyllodes tumor
Washington (Madigan Army Medical Center) - Benign Phyllodes tumor (12)
Washington (Seattle Veterans Medical Center) - Phyllodes tumor
West Virginia (Greenbrier Valley Medical Center) - Phyllodes tumor
Australia (Royal Hobart Hospital) - Benign Phyllodes tumor
Australia (Royal Prince Alfred Hospital) - Benign Phyllodes tumor
Australia (Sullivan Nicolaides Pathology) - Phyllodes tumour, borderline, breast
Canada, Saskatoo - Benign Phyllodes tumor
Canada (University Hospital of Sherbrooke) - Low grade Phyllodes tumor
Germany, Hamburg - Phyllodes tumor
Ireland (Galway Residents) - Phyllodes tumor of breast, benign
Ireland (Kerry General Hospital) - Benign phyllodes tumor
Japan (Asashi General Hospital) - Phyllodes tumor, benign
Japan (Kyoto University Hospital) - Phyllodes tumor, benign
Netherlands, Amstelveen - Benign Phyllodes tumor of the breast
Qatar (Hamad Medical Corporation) - Phyllodes tumor-benign
United Kingdom (John Radcliffe Hospital) - Benign Phyllodes tumor, breast

Case 5 - Diagnosis:

Phyllodes tumor, histologically benign, breast
T-04000, M-90213

Case 5 - References:

Gurley J and Muglia LJ . Cystosarcoma Phyllodes. *J Pediatr Endocrinol Metab* 2007; 20(1):19.
Esposito NN, Mohan D, Brufsky A, et al. Phyllodes Tumor. A Clinicopathologic and Immunohistochemical Study of 30 Cases. *Arch Pathol Lab* Med 2006; 130(10):1516-1521.
Dillion MF, Quinn CM, McDermott EW, et al. Needle Core Biopsy in the Diagnosis of Phyllodes Neoplasm. *Surg* 2006; 140(5):779-784.
Confavreux C, Lurkin A, Mitton N, et al. Sarcomas and Malignant Phyllodes Tumors of the Breast. A Retrospective Study. *Eur J Cancer* 2006; 42(16):2715-2721.

Case No. 6, Accession No. 29993 March 2007 A

Baldwin Park (Kaiser Permanente) - Kikuchis (2)
Claremont - Langerhan's cell histiocytosis
Clovis - Malignant (T-cell lymphoma) vs. histiocytosis (r/o Rosai-Dorfman), lymph node
Granada Hills - Roasi Dorfman disease
Long Beach (Long Beach Veterans Group) - Malignant histiocytic neoplasm (2)
Monterey (Community Hospital of Monterey Peninsula) - Histiocytic sarcoma vs. Rosai-Dorfman
Monterey Park (Garfield Medical Center) - Histiocytic lymphoma
Oakland - Histiocytosis /Hodgkins
Oakland (Alameda County Medical Center) - Histiocytic sarcoma
Orange (Kaiser Permanente) - Rosai-Dorfman disease
Oxnard (St. John's Regional Medical Center) - Histiocytic lymphadenitis (5)
Sacramento (UC Davis Residents) - Histiocytic necrotizing lymphadenitis (Kikuchis disease)
San Diego - Lymphoma, histiocytic
San Diego (Naval Medical Center) - Necrotizing lymphandenitis
San Diego (UCSD) - Rule out Rosai-Dorfman disease (2)
San Francisco (SF General Hospital) - T-cell rich B-cell lymphoma
Santa Barbara - Kikuchi's disease
Santa Rosa (Santa Rosa Memorial Hospital) - Histiocytic sarcoma (3)
Sonoma (Sonoma Valley Hospital) - Lymphadenitis/T-cell rich large B-cell
Woodland Hills - Histiocytic sarcoma
Woodland Hills (Suda's Soldiers) - Histiocytic sarcoma
Alabama (Baptist Medical Center) - Necrotizing lymphadenitis
Colorado, Ft Collins - Kikuchis disease (necrotizing histiocytic lymphadenitis
Florida (Baptist Hospital) - Kikuchis disease (4)

Florida (Munroe Regional Medical Center) - Necrotizing lymphadenitis, rule out TB vs. bacillary angiomalosis
Georgia, Decatur - Suggestive of Kikuchis lymphadenitis
Illinois, Burr Ridge - Inflammator pseudotumor of lymph node
Illinois (Loyola University of Chicago) - Kikuchi
Indiana (Howard Regional Medical Center) - Metastatic carcinoma (? acinic cell)
Iowa (Winneshiek Medical Center) - Non-Hodgkin's lymphoma
Kansas (Cytocheck Lab) - Hodgkin's lymphoma (1); Reactive lymphadenapathy, Kikuchi vs. others (1)
Kentucky (University of Louisville) - Kikuchi's lymphadenitis
Louisiana (Louisiana State University Medical Center) - Kikuchi's lymphadenitis
Massachusetts (Berkshire Medical Center) - Lymphoma (histiocyte rich T-cell or T-cell rich B-cell vs. histiocytic sarcoma
Massachusetts (Beverly Hospital) - Malignant histiocytosis
Massachusetts, Peabody - Necrotizing lymphadenitis
Massachusetts (Tufts New England Medical Center) - Kikuchi's disease
Michigan (Oakwood Hospital) - Rosai-Dorfman disease
Montana, Missoula - Kikuchi disease
Nebraska (Creighton University) - Histiocytic sarcoma
New Mexico, Albuquerque - Malignant "histiocytosis"
New York (Long Island Jewish Medical Center) - Necrotizing histiocytic lymphadenitis (Kikuchi's)
New York (Nassau University Medical Center) - Inflammatory malignant histiocytoma
New York (Stony Brook University Hospital Residents) - Kikuchi-Fujimoto disease
New York (SUNY Downstate Medical Center) - Necrotizing lymphadenitis (Kikuchi-Fujimoto disease)
North Carolina (Mountain Area Pathology) - Kikuchi-Fujimoto lymphadenitis (2); Solitary fibrous tumor (1)
Ohio (Northside Hospital) - Rosai-Dorfman disease
Oklahoma, Tulsa - Kikuchi-Fujimoto lymphadenopathy
Pennsylvania (Conemaugh Memorial Medical Center) - Histiocytic sarcoma
Pennsylvania (Drexel University College of Medicine) - Kikuchi's disease
Pennsylvania (Lehigh Valley Hospital) - Histiocytic sarcoma
Pennsylvania (Magee Women's Hospital) - Anaplastic large cell lymphoma
Pennsylvania (Mt Nittany Medical Center) - Sinus histiocytosis with massive lymphadenopathy (SHML), lymph nodes
Pennsylvania (Pennsylvania Hospital Residents) - Kikuchi-Fujimoto disease
Tennessee, Kingsport - Rosai-Dorfman disease, (sinus Histiocytosis with massive lymphadenopathy)
Texas, Crystal Beach - Necrotizing lymphadenitis consistent with histiocytosis (Kikuchi possible)
Texas, Houston - Necrotizing lymphadenitis
Texas, Lubbock - Histiocytic sarcoma
Texas, Sugarland - Histiocytic sarcoma
Washington (Madigan Army Medical Center) - Histiocytic necrotizing lymphadenitis (12)
Washington (Seattle Veterans Medical Center) - Malignant histiocytic neoplasm
West Virginia (Greenbrier Valley Medical Center) - Rosai-Dorfman disease
Australia (Royal Hobart Hospital) - Histiocytic necrotizing lymphadenitis (Kikuchi)
Australia (Royal Prince Alfred Hospital) - Malignant lymphoma, histiocytic type
Australia (Sullivan Nicolaides Pathology) - Atypical histiocytic infiltration, infectious cause
Canada, Saskatoon - Histiocytic necrotizing lymphadenitis
Canada (University Hospital of Sherbrooke) - Kikuchi-Fujmoto disease
Germany, Hamburg - Necrotizing lymphadenitis
Ireland (Galway Residents) - Histiocytic sarcoma (1); Large cell lymphoma-anaplastic (1)
Ireland (Kerry General Hospital) - Rosai-Dorfman disease
Japan (Asashi General Hospital) - Histocytic necrotizing lymphadenitis
Japan (Kyoto University Hospital) - Necrotizing lymphadenitis
Netherlands, Amstelveen - Histiocytic necrotizing lymphadenitis
Qatar (Hamad Medical Corporation) - Interdigitating dendritic cell tumor (3); Malignant histiocytic lymphoma (2)
United Kingdom (John Radcliffe Hospital) - Kikuchi lymphadenitis

Case 6 - Diagnosis:

Histiocytic necrotizing lymphadenitis (Kikuchi-Fujimoto disease). Cannot rule out T-cell lymphoma.
T-08000, M-40000

Consultation: Hun Kim, M.D., Oncolabs: "Kikuchi-Fujimoto disease, rule out T-cell lymphoma."

Case 6 - References:

Altuntas F, Sari I, Canoz O, et al. Kikuchi-Fujimoto Disease. A Rare But Important Cause of Fever and Lymphadenopathy in Pregnant Women. *Am J Hematol* 2006; 81(2):118-120.
Lee KY, Yeon YH and Lee BC. Kikuchi_Fujimoto Disease With Prolonged Fever in Children. *Pediatrics* 2004; 114(6):752-756.

Parappil A, Rifaath AA, Doi SA, et al. Pyrexia of Unknown Origin. Kikuchi-Fujimoto Disease. *Clin Infect Dis* 2004; 39(1):138-143.
Bosch X, Gilabert A, Miquel R, et al. Enigmatic Kikuchi-Fujimoto Disease. A Comprehensive Review. *Am J Clin Pathol* 2004; 122(1):141-152.
Onciu M and Medieiros LJ. Kikuchi-Fujimoto Lymphadenitis. *Adv Anat Pathol* 2003; 10(4):204-211.

Case No. 7, Accession No. 30054 March 2007 A

Baldwin Park (Kaiser Permanente) - Leiomyosarcoma (1); Myxoid leiomyoma (1); Benign metastasizing leiomyoma vs. primary pulmonary leiomyoma
Claremont - Leiomyoma
Clovis - Low grade spindle cell (myxoid leiomyoma vs solitary fibrous tumor, lung
Glendale - Inflammatory myofibroblastic tumor
Granada Hills - Leiomyoma
Long Beach (Long Beach Veterans Group) - Inflammatory pseudotumor (2)
Monterey (Community Hospital of Monterey Peninsula) - Inflammatory myofibroblastic tumor
Monterey Park (Garfield Medical Center) - Cellular leiomyoma
Oakland - Sarcoma, synovial
Oakland (Alameda County Medical Center) - Intrapulmonary fibrous tumor vs. inflammatory myofibroblastic tumor
Orange (Kaiser Permanente) - Myxofibrosarcoma, low grade
Oxnard (St. John's Regional Medical Center) - Schwannoma (2); Spindle cell lesion, metastatic smooth muscle tumor (1); Peripheral nerve sheath tumor (2)
Sacramento (UC Davis Residents) - Inflammatory myofibroblastic tumor
San Diego - Leiomyoma, lung
San Diego (Naval Medical Center) - Inflammatory myofibroblastic tumor
San Diego (UCSD) - Inflammatory pseeudotumor (myofibroblastic tumor) (2)
San Francisco (SF General Hospital) - Soliltary fibrous nodule
Santa Barbara - Leiomyoma
Santa Rosa (Santa Rosa Memorial Hospital) - Inflammatory myofibroblastic tumor (3)
Sonoma (Sonoma Valley Hospital) - Leiomyoma
Woodland Hills - Myxoid leiomyosarcoma
Woodland Hills (Suda's Soldiers) - Myxoid leiomyosarcoma
Alabama (Baptist Medical Center) - Inflammatory myofibroblastic pseudotumor
Colorado, Ft Collins - Inflammatory myofibroblastic tumor
Florida (Baptist Hospital) - Inflammatory pseudotumor (3); Myxoid fibrous histiocytoma (1)
Florida (Munroe Regional Medical Center) - Solitary fibrous tumor
Georgia, Decatur - Metastatic leiomyosarcoma
Illinois, Burr Ridge - Inflammatory myofibroblastic tumor (1); Myxoid leiomyosarcoma, lung (1)
Illinois (Loyola University of Chicago) - Leiomyoma
Indiana (Howard Regional Medical Center) - Metastasizing leiomyoma
Iowa (Winneshiek Medical Center) - Fibrohistiocytic tumor
Kansas (Cytocheck Lab) - Leiomyosarcoma (1); Fibroleiomyomatous hamartoma (1)
Kentucky (University of Louisville) - Inflammatory myofibroblastic tumor
Louisiana (Louisiana State University Medical Center) - Leiomyoma
Massachusetts (Berkshire Medical Center) - Nodular fasciitis
Massachusetts (Beverly Hospital) - Solitary fibrous tumor
Massachusetts, Peabody - Inflammatory myofibroblastic tumor, lung
Massachusetts (Tufts New England Medical Center) - Inflammatory myofibroblastic tumor
Michigan (Oakwood Hospital) - Inflammatory pseudotumor
Montana, Missoula - Leiomyosarcoma
Nebraska (Creighton University) - Myofibroma
New Mexico, Albuquerque - Myxofibrosarcoma
New York (Long Island Jewish Medical Center) - Inflammatory myofibroblasatic tumor
New York (Nassau University Medical Center) - Myxoid leiomyoma
New York (Stony Brook University Hospital Residents) - Inflammatory myofibroblastic tumor
New York (SUNY Downstate Medical Center) - Inflammatory myofibroblastic tumor
North Carolina (Mountain Area Pathology) - Inflammatory myofibroblastic tumor (1); Kikuchi's disease (1)
Ohio (Northside Hospital) - Inflammatory myofibroblastic tumor
Oklahoma, Tulsa - Myofibroblastic tumor
Pennsylvania (Conemaugh Memorial Medical Center) - Inflammatory myofibroblastic tumor
Pennsylvania (Drexel University College of Medicine) - Pulmonary inflammatory myofibroblastic tumor
Pennsylvania (Lehigh Valley Hospital) - Inflammatory pseudotumor of lung

Pennsylvania (Magee Women's Hospital) - Pulmonary artery ?
Pennsylvania (Mt Nittany Medical Center) - Inflammatory myofibroblastic tumor, rt lung
Pennsylvania (Pennsylvania Hospital Residents) - Inflammatory myofibroblastic tumor
Tennessee, Kingsport - Leiomyoma
Texas, Crystal Beach - Leiomyoma
Texas, Houston - Leiomyoma
Texas, Lubbock - Leiomyosarcoma
Texas, Sugarland - Inflammatory myofibroblastic tumor
Washington (Madigan Army Medical Center) - Leiomyoma (7); Inflammatory pseudotumor (5)
Washington (Seattle Veterans Medical Center) - Leiomyoma
West Virginia (Greenbrier Valley Medical Center) - Solitary fibrous tumor
Australia (Royal Hobart Hospital) - Inflammatory myofibroblastic tumour
Australia (Royal Prince Alfred Hospital) - Spindle cell neoplasm/myofibroblastic
Australia (Sullivan Nicolaides Pathology) - Smooth muscle tumour/secondary/primary, lung
Canada, Saskatoon - Leiomyoma, myxoid degeneration
Canada (University Hospital of Sherbrooke) - Inflammatory myofibroblastic tumor
Germany, Hamburg - Inflammatory pseudotumor
Ireland (Galway Residents) - Inflammatory pseudotumor of lung
Ireland (Kerry General Hospital) - Leiomyosarcoma, metastatic
Japan (Asashi General Hospital) - Myxoid leiomyosarcoma
Japan (Kyoto University Hospital) - Inflammatory myofibroblastic tumor
Netherlands, Amstelveen - Inflammatory myofibroblastic tumor of the lung
Qatar (Hamad Medical Corporation) - Leiomyoma (3); Inflammatory myofibroblastic tumor (2)
United Kingdom (John Radcliffe Hospital) - Myxoid leiomyoma

Case 7 - Diagnosis:

Inflammatory myofibroblastic tumor, lung
T-28000, M-03090

Consultation: Juan Rosai, M.D. Milan, Italy, "Inflammatory myofibroblastic tumor."

Case 7 - References:

Sirvent N, Coindre JM and Pedeutour F. Inflammatory Myofibroblastic Tumors. *Ann Pathol* 2002; 22(6):453-460.
Yamaguchi M, Yoshino I, Osoegawa A, et al. Inflammatory Myofibroblastic Tumor of the Mediastinum Presenting as Superior Vena Cava Syndrome. *J Thorac Cardiovasc Surg* 2003; 126(3):870-872.
Dehner LP. Inflammatory Myofibroblastic Tumor. The Continued Definition of One Type of So-Called Inflammatory Pseudotumor. *Am J Surg Pathol* 2004; 28(12):1609-1614.
Kovach SJ, Fischer AC, Katzman PJ, et al. Inflammatory Myofibroblastic Tumors. *J Surg Oncol* 2006; 94(5):385-391.
Kim TS, Han J, Kim GY, et al. Pulmonary Inflammatory Pseudotumor (Inflammatory Myofibroblastic Tumor. CT Features With Pathologic Correlation. *J Comput Assist Tomogr* 2005; 29(5):633-639.
Nonaka D, Birbe R and Rosai J. So-Called Inflammatory Myofibroblastic Tumour. A Proliferative Lesion of Fibroblastic Reticulum Cells? *Histopathol* 2005; 46(6):604-613.

Case No. 8, Accession No. 29623 March 2007 A

Baldwin Park (Kaiser Permanente) - Gastrointestinal stromal tumor (3)
Claremont - Gastrointestinal stromal tumor
Clovis - Mesentery/Desmoid tumor (mesenteritis)
Glendale - Aggressive mesenteric fibromatosis
Granada Hills - Stromal tumor
Long Beach (Long Beach Veterans Group) - Gastrointestinal stromal tumor, malignant
Monterey (Community Hospital of Monterey Peninsula) - Fibromatosis
Monterey Park (Garfield Medical Center) - Low grade gastrointestinal stromal tumor
Oakland - Gastrointestinal stromal tumor
Oakland (Alameda County Medical Center) - Intra-abdominal fibromatosis
Orange (Kaiser Permanente) - Gastrointestinal stromal tumor, malignant
Oxnard (St. John's Regional Medical Center) - Gastrointestinal stromal tumor (5)
Sacramento (UC Davis Residents) - Gastrointestinal stromal tumor
San Diego - Gastrointestinal stromal tumor, mesentery
San Diego (Naval Medical Center) - Intra-abdominal fibromatosis
San Diego (UCSD) - Fibromatosis (2)

San Francisco (SF General Hospital) - Gastrointestinal stromal tumor
Santa Barbara - Fibromatosis
Santa Rosa (Santa Rosa Memorial Hospital) - Extra gastrointestinal stromal tumor (3)
Sonoma (Sonoma Valley Hospital) - Gastrointestinal stromal tumor, high risk
Woodland Hills - Mesenteric fibromatosis
Woodland Hills (Suda's Soldiers) - Fibromatosis
Alabama (Baptist Medical Center) - Gastrointestinal stromal tumor
Colorado, Ft Collins - Fibromatosis
Florida (Baptist Hospital) - Gastrointestinal stromal tumor (4)
Florida (Munroe Regional Medical Center) - Gastrointestinal stromal tumor
Georgia, Decatur - Fibromatosis
Illinois, Burr Ridge - Gastrointestinal stromal tumor (1); Fibromatosis, mesentery (1)
Illinois (Loyola University of Chicago) - Gastrointestinal stromal tumor
Indiana (Howard Regional Medical Center) - Desmoid tumor (fibromatosis)
Iowa (Winneshiek Medical Center) - Proliferative fasciitis
Kansas (Cytocheck Lab) - Stromal tumor (1); Gastrointestinal stromal tumor (1)
Kentucky (University of Louisville) - Malignant gastrointestinal stromal tumor
Louisiana (Louisiana State University Medical Center) - Gastrointestinal stromal tumor
Massachusetts (Berkshire Medical Center) - Gastrointestinal stromal tumor, desmoid
Massachusetts (Beverly Hospital) - Gastrointestinal stromal tumor
Massachusetts, Peabody - Inflammatory myofibroblastic tumor, mesentery
Massachusetts (Tufts New England Medical Center) - Fibromatosis
Michigan (Oakwood Hospital) - Fibromatosis
Montana, Missoula - Gastrointestinal stromal tumor
Nebraska (Creighton University) - Gastrointestinal stromal tumor
New Mexico, Albuquerque - Extra-gastrointestinal stromal tumor
New York (Long Island Jewish Medical Center) - Gastrointestinal stromal tumor
New York (Nassau University Medical Center) - Gastrointestinal stromal tumor
New York (Stony Brook University Hospital Residents) - Fibromatosis
New York (SUNY Downstate Medical Center) - Deep fibromatosis
North Carolina (Mountain Area Pathology) - Gastrointestinal stromal tumor (3)
Ohio (Northside Hospital) - Fibromatosis
Oklahoma, Tulsa - Gastrointestinal stromal tumor
Pennsylvania (Conemaugh Memorial Medical Center) - Gastrointestinal stromal tumor
Pennsylvania (Drexel University College of Medicine) - Fibromatosis
Pennsylvania (Lehigh Valley Hospital) - Gastrointestinal stromal tumor
Pennsylvania (Magee Women's Hospital) - Deep fibromatosis
Pennsylvania (Mt Nittany Medical Center) - Gastrointestinal stromal tumor (GIST) with myxoid stroma and skeinoid fibers, small bowel
Pennsylvania (Pennsylvania Hospital Residents) - Mesenteric fibromatosis
Tennessee, Kingsport - Gastrointestinal stromal tumor
Texas, Crystal Beach - Gastrointestinal stromal tumor
Texas, Houston - Gastrointestinal stromal tumor
Texas, Lubbock - Malignant solitary fibrous tumor
Texas, Sugarland - Gastrointestinal stromal tumor
Washington (Madigan Army Medical Center) - Fibromatosis (12)
Washington (Seattle Veterans Medical Center) - Gastrointestinal stromal tumor, uncertain metastatic potential
West Virginia (Greenbrier Valley Medical Center) - Gastrointestinal stromal tumor
Australia (Royal Hobart Hospital) - Desmoid fibromatosis
Australia (Royal Prince Alfred Hospital) - Retroperitoneal fibromatosis
Australia (Sullivan Nicolaides Pathology) - Gastrointestinal stromal tumour, mesentery
Canada, Saskatoon - Gastrointestinal stromal tumor
Canada (University Hospital of Sherbrooke) - Gastrointestinal stromal tumor
Germany, Hamburg - Gastrointestinal stromal tumor
Ireland (Galway Residents) - Mesenteric fibromatosis/intra-abdominal desmoid
Ireland (Kerry General Hospital) - Gastrointestinal stromal tumor
Japan (Asashi General Hospital) - Gastrointestinal stromal tumor
Japan (Kyoto University Hospital) - Gastrointestinal stromal tumor
Netherlands, Amstelveen - Gastrointestinal stromal tumor of the mesentery
Qatar (Hamad Medical Corporation) - Gastrointestinal stromal tumor, borderline
United Kingdom (John Radcliffe Hospital) - Gastrointestinal stromal tumor

Case 8 - Diagnosis:

Mesenteric fibromatosis (CD117-positive)
T-Y4100, M-76100

Directors Note: "Many tumors, other than GIST are now being shown to regularly or sporadically express CD117, the clinical significance of which is uncertain. The morphology of this tumor included long-sweeping fascicles (on most, but not all slides) and has the morphology of an intra-abdominal fibromatosis." (drc)

Case 8 – References:

Rodriguez JA, Guarda LA and Rosai J. Mesenteric Fibromatosis with Involvement of the Gastrointestinal Tract. A GIST Simulator. A Study of 25 Cases. *Am J Clin Pathol* 2004; 121(1):93-98.

Pai SA and Zaveri SS. Intra-Abdominal Fibromatosis of the Jejunum and Mesentery. *J Clin Pathol* 2004; 57(10):1119.

Montgomery E, Torbenson MS, Kaushal M, et al. Beta-Caterin Immunohistochemistry Separates Mesenteric Fibromatosis From Gastrointestinal Stromal Tumor and Sclerosing Mesenteritis. *Am J Surg Pathol* 2002; 26(10):1296-1301.

Azizi L, Balu M, Belkacem A, et al. MRI Features of Mesenteric Desmoid Tumors in Familial Adenomatous Polyposis. *AJR Am J Roentgenol* 2005; 184(4):1128-1135.

Church J, Berk T, Boman BM, et al. Staging Intra-Abdominal Desmoid Tumors in Familial Adenomatous Polyposis. A Search for a Uniform Approach to a Troubling Disease. *Dis Colon Rectum* 2005; 48(8):1528-1534.

Case No. 9, Accession No. 29613 March 2007 A

Baldwin Park (Kaiser Permanente) - Schwannoma (2); Benign nerve sheath tumor (features of neurofibroma) (1)
Claremont - Schwannoma
Clovis - Mediastinum, neurilemmoma
Glendale - Schwannoma
Granada Hills - Schwanoma
Long Beach (Long Beach Veterans Group) - Schwannoma (2)
Monterey (Community Hospital of Monterey Peninsula) - Schwannoma
Monterey Park (Garfield Medical Center) - Schwannoma, benign
Oakland - Neurofibroma
Oakland (Alameda County Medical Center) - Schwannoma
Orange (Kaiser Permanente) - Peripheral nerve sheath tumor
Oxnard (St. John's Regional Medical Center) - Neurilemmoma (3); Nerve sheath tumor (2)
Sacramento (UC Davis Residents) - Schwanoma
San Diego - Schwannoma, posterior mediastinum
San Diego (Naval Medical Center) - Neurofibroma
San Diego (UCSD) - Schwannoma (2)
San Francisco (SF General Hospital) - Schwannoma
Santa Barbara - Neurofibroma
Santa Rosa (Santa Rosa Memorial Hospital) - Schwannoma (3)
Sonoma (Sonoma Valley Hospital) - Schwannoma
Woodland Hills - Schwannoma
Woodland Hills (Suda's Soldiers) - Myxoma
Alabama (Baptist Medical Center) - Neurofibroma
Colorado, Ft Collins - Schwanoma
Florida (Baptist Hospital) - Neurofibroma (3); Schwannoma (1)
Florida (Munroe Regional Medical Center) - Neurofibroma
Georgia, Decatur - Neurofibroma
Illinois, Burr Ridge - Peripheral nerve sheath tumor (1); Schwannoma, posterior mediastinum (1)
Illinois (Loyola University of Chicago) - Schwannoma
Indiana (Howard Regional Medical Center) - Schwannoma
Iowa (Winneshiek Medical Center) - Schwannoma
Kansas (Cytocheck Lab) - Fibroma (1); Solitary fibrous tumor (1)
Kentucky (University of Louisville) - Schwannoma
Louisiana (Louisiana State University Medical Center) - Neurofibroma
Massachusetts (Berkshire Medical Center) - Schwannoma
Massachusetts (Beverly Hospital) - Neurofibroma
Massachusetts, Peabody - Schwannoma, mediastinum
Massachusetts (Tufts New England Medical Center) - Peripheral nerve sheath tumor
Michigan (Oakwood Hospital) - Schwannoma
Montana, Missoula - Schwannoma

Nebraska (Creighton University) - Myxoid neurofibroma
New Mexico, Albuquerque - Peripheral nerve sheath tumor, neurofibroma
New York (Long Island Jewish Medical Center) - Benign peripheral nerve sheath tumor
New York (Nassau University Medical Center) - Schwannoma
New York (Stony Brook University Hospital Residents) - Neurofibroma
New York (SUNY Downstate Medical Center) - Schwannoma vs. neurofibroma
North Carolina (Mountain Area Pathology) - Schwannoma (2)
Ohio (Northside Hospital) - Schwannoma
Oklahoma, Tulsa - Schwannoma
Pennsylvania (Conemaugh Memorial Medical Center) - Schwannoma
Pennsylvania (Drexel University College of Medicine) - Neurofibroma
Pennsylvania (Lehigh Valley Hospital) - Schwannoma
Pennsylvania (Magee Women's Hospital) - Schwannoma
Pennsylvania (Mt Nittany Medical Center) - Neurofibroma, posterior mediastinum
Pennsylvania (Pennsylvania Hospital Residents) - Neurofibroma
Tennessee, Kingsport - Schwannoma
Texas, Crystal Beach - Schwannoma
Texas, Houston - Schwannoma
Texas, Lubbock - Neurilemmoma
Texas, Sugarland - Schwannoma
Washington (Madigan Army Medical Center) - Schwannoma (12)
Washington (Seattle Veterans Medical Center) - Schwannoma
West Virginia (Greenbrier Valley Medical Center) - Schwannoma
Australia (Royal Hobart Hospital) - Schwannoma
Australia (Royal Prince Alfred Hospital) - Neurofibroma DDx: Schwannoma
Australia (Sullivan Nicolaides Pathology) - Benign peripheral nerve sheath tumour, mediastinum
Canada, Saskatoon - Schwannoma
Canada (University Hospital of Sherbrooke) - Schwannoma
Germany, Hamburg - Schwannoma
Ireland (Galway Residents) - Neurilemmoma of mediastinum
Ireland (Kerry General Hospital) - Neurofibroma
Japan (Asashi General Hospital) - Schwannoma
Japan (Kyoto University Hospital) - Neurofibroma
Netherlands, Amstelveen - Neurofibroma
Qatar (Hamad Medical Corporation) - Neurofibroma
United Kingdom (John Radcliffe Hospital) - Neurofibroma

Case 9 - Diagnosis:

Schwannoma, mediastinum
T-Y2300, M-95600

Case 9 – References:

Chen HC, Huang HJ, Wu CY, et al. Esophageal Schwannoma With Tracheal Compression. *Thorac Cardiovasc Surg* 2006; 54(8):555-558.
Rausche T, El-Mokthari NE, Kruger D, et al. Benign Mediastinal Schwannoma. Cardiac Considerations. Case Report and a Short Review of the Literature. *Clin Res Cardiol* 2006; 95(8):422-424.
Kanzaki M, Ohtsuka T, Obara T, et al. Surgically Treated Dumbbell Schwannoma Arising in the Brachial Plexus With Intrathoracic Extension. *Jpn J Thorac Cardiovasc Surg* 2003; 51(2):62-64.
Georghiou GP, Vidne BA, Boikov O, et al. Giant Schwannoma of the Posterior Mediastinum. *Eur J Cardiothorac Surg* 2003; 24(6):1030.
Wick MR. Cystic Lesions of the Mediastinum. *Semin Diagn Pathol* 2005; 22(3):241-253.

Case No. 10, Accession No. 30553 March 2007 A

Baldwin Park (Kaiser Permanente) - Poorly differentiated carcinoma/squamous cell or adenosquamous carcinoma (1); Squamous cell carcinoma (1); Invasive poorly differentiated carcinoma (1)
Claremont - Pleomorphic carcinoma
Clovis - Retrorectal chordoma
Glendale - Chordoma
Granada Hills - Adenosquamous carcinoma, poorly differentiated

Long Beach (Long Beach Veterans Group) - Poorly differentiated carcinoma (1); Poorly differentiated muco-epidermoid carcinoma (1);
Monterey (Community Hospital of Monterey Peninsula) - Sarcomatoid/dedifferentiated chordoma
Monterey Park (Garfield Medical Center) - Atypical chordoma
Oakland - Rhabdomyosarcoma
Oakland (Alameda County Medical Center) - Chordoma
Orange (Kaiser Permanente) - Chordoma
Oxnard (St. John's Regional Medical Center) - Chondrosarcoma (2); Chordoma (1); Sarcoma (1); Myxoid malignant fibrous histiocytoma (1)
Sacramento (UC Davis Residents) - Chordoma
San Diego - Chordoma, retrorectal
San Diego (Naval Medical Center) - Poorly differentiated neoplasm, favor carcinoma
San Diego (UCSD) - Chordoma (2)
San Francisco (SF General Hospital) - Chordoma
Santa Barbara - Metastatic carcinoma
Santa Rosa (Santa Rosa Memorial Hospital) - Chordoma (3)
Sonoma (Sonoma Valley Hospital) - Apocrine mixed tumor
Woodland Hills - Squamous cell carcinoma (adenosquamous carcinoma)
Woodland Hills (Suda's Soldiers) - Chordoma
Alabama (Baptist Medical Center) - Chordoma
Colorado, Ft Collins - Chordoma
Florida (Baptist Hospital) - Chordoma (4)
Florida (Munroe Regional Medical Center) - Squamous cell carcinoma
Georgia, Decatur - Chordoma
Illinois, Burr Ridge - Squamous cell carcinoma, variant (1); Favor chordoma, rule out metastatic carcinoma (1)
Illinois (Loyola University of Chicago) - Chordoma
Indiana (Howard Regional Medical Center) - Chordoma
Iowa (Winneshiek Medical Center) - Chordoid tumor
Kansas (Cytocheck Lab) - Adenocarcinoma, clear cell (1); Carcinoma, NOS (1)
Kentucky (University of Louisville) - Chordoma vs. poorly differentiated carcinoma
Louisiana (Louisiana State University Medical Center) - Chondroid chordoma
Massachusetts (Berkshire Medical Center) - Chordoma, malignant (vs. carcinoma)
Massachusetts (Beverly Hospital) - Chordoma
Massachusetts, Peabody - Chordoma, retrorectal
Massachusetts (Tufts New England Medical Center) - Chordoma
Michigan (Oakwood Hospital) - Chordoma or metastatic carcinoma
Montana, Missoula - Mucinous carcinoma
Nebraska (Creighton University) - Poorly differentiated adenocarcinoma with signet ring features
New Mexico, Albuquerque - Chondrosarcoma
New York (Long Island Jewish Medical Center) - Chordoma
New York (Nassau University Medical Center) - Chordoma
New York (Stony Brook University Hospital Residents) - Chordoma
New York (SUNY Downstate Medical Center) - Dedifferentiated chordoma
North Carolina (Mountain Area Pathology) - Chordoma (3)
Ohio (Northside Hospital) - Chordoma
Oklahoma, Tulsa - Chordoma
Pennsylvania (Conemaugh Memorial Medical Center) - Chordoma
Pennsylvania (Drexel University College of Medicine) - Malignant chordoma
Pennsylvania (Lehigh Valley Hospital) - Chordoma
Pennsylvania (Magee Women's Hospital) - Pleomorphic liposarcoma
Pennsylvania (Mt Nittany Medical Center) - Chordoma, sacrococcygeal region
Pennsylvania (Pennsylvania Hospital Residents) - Chordoma
Tennessee, Kingsport - Metastatic mucinous carcinoma (adenocarcinoma)
Texas, Crystal Beach - Squamous cell carcinoma
Texas, Houston - Chondrosarcoma
Texas, Lubbock - Mucinous adenocarcinoma
Texas, Sugarland - Epithelioid angiosarcoma
Washington (Madigan Army Medical Center) - Metaplastic carcinoma (2); Indecisive and weak (10)
Washington (Seattle Veterans Medical Center) - Chondroma
West Virginia (Greenbrier Valley Medical Center) - Carcinoma, NOS
Australia (Royal Hobart Hospital) - Chordoma
Australia (Royal Prince Alfred Hospital) - Chordoma
Australia (Sullivan Nicolaides Pathology) - Chordoma

Canada, Saskatoon - Chordoma
Canada (University Hospital of Sherbrooke) - Chordoma
Germany, Hamburg - Chordoma
Ireland (Galway Residents) - Poorly differentiated carcinoma/signet ring adenocarcinoma
Ireland (Kerry General Hospital) - Chordoma
Japan (Asashi General Hospital) - Chordoma
Japan (Kyoto University Hospital) - Chordoma
Netherlands, Amstelveen - Metastatic mucinous adenocarcinoma
Qatar (Hamad Medical Corporation) - Chordoma
United Kingdom (John Radcliffe Hospital) - Chordoma

Case 10 - Diagnosis:

Chordoma, sacrococcygeal ("retro-rectal")
T-Y2300, M-95600

Case 10 - References:

Atalar H, Selek H, Yildiz Y, et al. Management of Sacrococcygeal Chordomas. *Int Orthop* 2006; 30(6):512-518.
Chandawarkar RY. Sacrococcygeal Chordoma. Review of 50 Consecutive Patients. *World J Surg* 1996; 20(6):717-719.
Klingler L, Trammell R, Allan DG, et al. Clonality Studies in Sacral Chordoma. *Cancer Genet Cytogenet* 2006; 171(1):68-71.
McPherson CM, Suki D, McCutcheon IE, et al. Metastatic Disease From Spinal Chordoma. A 10-Year Experience. *J Neurosurg Spine* 2006; 5(4):277-280.
Fan F, Templeton K and Damjanov I. Epithelioid Cellular Chordoma of the Sacrum. A Potential Diagnostic Problem. *Ann Diag Pathol* 2005; 9(3):139-142.
Gui X; Siddiqui NH and Guo M. Physaliphorous Cells in Chordoma. *Arch Pathol Lab Med* 2004; 128(12):1457-1458.