CALIFORNIA
TUMOR TISSUE REGISTRY

Small Round Blue Cell Tumors and Neuroendocrine Neoplasms

Study Cases, Subscription B

February, 2007

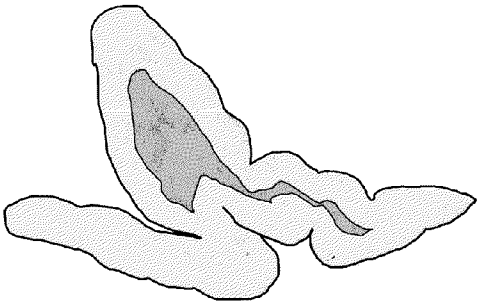

California Tumor Tissue Registry
c/o: Department of Pathology and Human Anatomy
Loma Linda University School of Medicine
11021 Campus Avenue, AH 335
Loma Linda, California 92350
(909) 558-4788
FAX: (909) 558-0188
E-mail: cttr@linkline.com
Web site & Case of the Month: www.cttr.org

Target audience:
Practicing pathologists and pathology residents.

Goal:
To acquaint the participant with the histologic features of a variety of benign and malignant neoplasms and tumor-like conditions.

Objectives:
The participant will be able to recognize morphologic features of a variety of benign and malignant neoplasms and tumor-like conditions and relate those processes to pertinent references in the medical literature.

Educational methods and media:
Review of representative glass slides with associated histories.
Feedback on consensus diagnoses from participating pathologists.
Listing of selected references from the medical literature.

Principal faculty:
Donald R. Chase, MD

CME Credit:
Loma Linda University School of Medicine designates this continuing medical education activity for up to 2 hours of Category I of the Physician's Recognition Award of the American Medical Association.
CME credit is offered for the subscription year only.

Accreditation:
Loma Linda University School of Medicine is accredited by the Accreditation Council for Continuing Medical Education (ACCME) to sponsor continuing medical education for physicians.

Contributor: H. V. O'Connell, M.D. **Case No. 1 - February, 2007 B**
Bakersfield, CA

Tissue from: Thyroid **Accession #15082**

Clinical Abstract:

After complaining of choking spells, especially at night, this 54-year-old woman was found to have a rapidly enlarging neck mass. Thyroid scan and function studies were not contributory. Past medical history included cervical cancer thirteen years previously, which was treated with radiation therapy.

Gross Pathology:

The 65 gram specimen consisted of multiple pieces of tissue, some of which were smooth and glistening and others were flat, homogeneous and white.

Special Studies:

Chromogranin:	negative
NSE:	weakly positive
Synaptophysin:	negative
CD45:	positive
CD68:	equivocal
Cytokeratin:	negative
Thyroglobulin:	non-specific

Contributor: W. F. Pezzlo, M.D. **Case No. 2 - February, 2007 B**
Orange, CA

Tissue from: Thyroid **Accession #23615**

Clinical Abstract:

A 54-year-old woman presented with a 10-year history of bilateral thyroid enlargement. Thyroid function studies were negative. A preoperative calcitonin level was not performed. The chest x-ray was interpreted as showing pulmonary metastases. A total thyroidectomy was performed. Fifteen years earlier, her 73 year old father had been treated for papillary thyroid carcinoma.

Gross Pathology:

Within the right thyroid lobe was a 150 gram encapsulated mass. The cut surface was gray to yellow and focally cystic.

Contributor: Gabriel Haiby, M.D. **Case No. 3 - February, 2007 B**
Encino, CA

Tissue from: Thyroid **Accession #19642**

Clinical Abstract:

After a 30-year history of goiter, this 51-year-old man presented with tracheal obstruction associated with recent thyroid enlargement. Thyroid studies, including calcitonin, were reported as normal.

Gross Pathology:

The specimen consisted of two lobules, one measuring 5.0 x 3.0 x 1.5 cm, and the other measuring 3.0 x 3.2 x 1.5 cm. The thyroid was closely adherent to the peritracheal tissue.

Contributor: William Cowell, M.D. **Case No. 4 - February, 2007 B**
Oceanside, CA

Tissue from: Lung **Accession #20347**

Clinical Abstract:

For about 10 months, this 36-year-old man had been experiencing dull, vague pains across the anterior upper chest. He had a cough productive of small to moderate quantities of mucoid sputum, which was occasionally tinged with blood. Chest x-ray disclosed a 3 x 3 cm mass in the central portion of the upper lobe of the left lung. Skin tests were negative for *Coccidioides*, *Histoplasma* and PPD. The patient had smoked ½ to ¾ packs of cigarettes per day.

Gross Pathology:

The 455 gram, 18.0 x 13.0 x 5.5 cm left lung contained a large, firm mass in the upper lobe. One of the tertiary bronchi appeared to lead into the neoplasm. The tumor itself consisted of several nodules, each approximately 2.5 cm in diameter. The tumor was smooth and homogeneous pale, gray tan.

Contributor: Jin Mei, M.D. **Case No. 5 - February, 2007 B**
Hangzhou, China

Tissue from: Kidney **Accession #30435**

Clinical Abstract:

A 68-year-old man presented with a nine-month history of recurrent hematuria. A mass was identified in the left kidney.

Gross Pathology:

The 13.0 x 10.0 x 6.5 cm kidney contained a poorly delineated, 9.0 x 6.5 x 5.0 cm mass involving the renal pelvis. The cut surface was gray, yellow and red.

Special Studies:

Chromogranin:	Focally positive
CAM 5.2:	Positive
Synaptophysin:	Positive

Contributor: Arno Roscher, M.D. **Case No. 6 - February, 2007 B**
Granada Hills, CA

Tissue from: Chest wall **Accession #23492**

Clinical Abstract:

During work-up for back pain, a chest x-ray identified a lung mass in this 62-year-old woman. After undergoing a lobectomy, she was given a regimen of chemotherapy. One year later, she presented with a mass in the left chest wall.

Gross Pathology:

The 11.0 x 7.0 cm skin ellipse covered a subjacent 5.0 cm mass. The well-circumscribed, slightly scalloped mass was dark red-brown.

Contributor: DeWitt Hunter, M.D. **Case No. 7 - February, 2007 B**
Santa Barbara, CA

Tissue from: Small bowel **Accession #23767**

Clinical Abstract:

During work-up for cholelithiasis, a 68-year-old man was found to have a 6 to 8 cm, movable, nonpulsatile lower abdominal mass. During surgery, the mass was found to involve much of the small bowel mesentery, extending to its root.

Gross Pathology:

A 14 cm long segment of edematous small bowel contained a yellow to pale tan firm mass extending from the mucosa through the muscularis into the mesentery.

Contributor: James Tenney, M.D. **Case No. 8 - February, 2007 B**
Reno, NV

Tissue from: Retroperitoneum **Accession #23999**

Clinical Abstract:

Six months after noting a painless epigastric mass, a 20-year-old man sought treatment from his physician. An upper GI series revealed displacement of the third portion of the duodenum by an extrinsic mass. A large retroperitoneal mass was surgically removed.

Gross Pathology:

The 240 gram specimen consisted of a 24.0 x 7.0 x 6.0 cm well-demarcated, encapsulated, red-tan mass with finely nodular, marked hemorrhagic cut surfaces.

Contributor: **M. Rose Akin, M.D.**
Fresno, CA

Case No. 9 - February, 2007 B

Tissue from: **Left chest wall**

Accession #30346

Clinical Abstract:

An 18-year-old man was found to have a left chest wall mass.

Gross Pathology:

The 166 gram specimen included a segment of rib with adherent skin, subcutaneous tissue and skeletal muscle. At mid-portion of the rib segment, the inner portion of the rib was adherent to a 6.0 x 5.2 x 4.0 cm well-circumscribed, ovoid, firm mass. Sectioning of the tumor revealed a homogenous tan-brown cut surface with focal hemorrhage.

Contributor: **Jozef Kollin, M.D.**
Lakewood, CA

Case No. 10 - February, 2007 B

Tissue from: **Inguinal nodes**

Accession #30368

Clinical Abstract:

Five months after undergoing excision and radiation therapy for a tumor of the right thigh, this 81-year-old woman was found to have enlarged groin nodes.

Gross Pathology:

The 6.0 cm lymph node was lobular, tan-gray and very soft, with areas of hemorrhage.