CALIFORNIA
TUMOR TISSUE REGISTRY

GASTROINTESTINAL TRACT AND GU PATHOLOGY

Minutes – Subscription B

January 2015

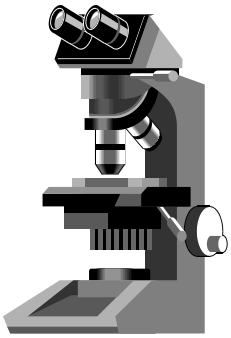

SUGGESTED READING (General Topics from Recent Literature):

Sciallis AP, Bedroske PP, et al. High Grade Endometrial Stromal Sarcomas: A Clinicopathologic Study of a Group of Tumors With Heterogenous Morphologc and Genetic Features. *Am J Surg Pathol* 2014; 38:1161-1172.

Hoyt B. and Bhawan J. Histological Spectrum of Cutaneous Herpes Infections. *Am J Dermatopathol* 2014; 36:609-619.

Sidiropoulos M, Sholl LM, et al. Desmoplastic Nevus of Chronically Sun-Damaged Skin. An Entity to Be Distinguished From Desmoplastic Melanoma. *Am J Dermatopathol* 2014; 36:629-634.

Chevarie-Davis M, et al. The Morphologic and Immunohistochemical Spectrum of Papillary Renal Cell Carcinoma: Study Including 132 Cases With Pure Type 1 and Type 2 Morphology as Well as Tumors With Overlapping Features. *Am J Surg Pathol* 2014; 38:887-894.

Arnold MA, Schoenfield L, et al. Diagnostic Pitfalls of Differentiating Desmoplastic Small Round Cell Tumor (DSRCT) From Wilms Tumor (WT): Overlapping Morphologic and Immunohistochemical Features. *Am J Surg Pathol* 2014; 38:1220-1226.

California Tumor Tissue Registry
c/o: Department of Pathology and Human Anatomy
Loma Linda University School of Medicine
11021 Campus Avenue, AH 335
Loma Linda, California 92350
(909) 558-4788
FAX: (909) 558-0188
E-mail: cttr@linkline.com
Web site & Case of the Month: www.cttr.org

FILE DIAGNOSES

CTTR Subscription B January 2015

Case 1:
Cavernous hemangioma, liver

Case 2:
Hepatobiliary mucinous cystadenoma

Case 3:
Cholangiocarcinoma, liver

Case 4:
Solid pseudopapillary neoplasm, pancreas

Case 5:
Mucinous cystic neoplasm of pancreas with moderate dysplasia

Case 6:
Leiomyosarcoma, small intestine

Case 7:
Mucinous adenocarcinoma with signet ring cell features, gallbladder

Case 8:
Adult polycystic kidney disease

Case 9:
Angiomyolipoma, kidney

Case 10:
High grade invasive papillary urothelial carcinoma, bladder

Case No. 1, Accession No. 31881 January 2015

Glendale - Cavernous hemangioma
Orinda (Kaiser Permenente) - Hemangioma
San Diego (Naval Medical Center) - Cavernous hemangioma
San Francisco (UCSF) - Hereditary hemorrhagic telangiectasia
San Jose - Hemangioma
Torrence (Harbor-UCLA Medical Center) - Lymphangioma
Alabama (Cunningham Pathology) - Angiosarcoma
Connecticut (Danbury Hospital) - Cavernous hemangioma-papillary endothelial hyperplasia
Delaware (Armed Forces Medical Examiner System) - Cavernous hemangioma
Illinois (Heartland Regional Medical Center) - Hemangioma
Illinois, Oak Brook - Cavernous hemangioma
Maryland (University of Maryland Medical Center) - Hemangioma
Maryland (Walter Reed NMMC) - Hemangioma
North Carolina, Clemmons - Cavernous hemangioma
Ohio (The University of Toledo Medical Center Residents) - Cavernous hemangioma
Oregon (Oregon Health Science University Residents) - Cavernous hemangioma
Pennsylvania (Drexel University College of Medicine Residents) - Cavernous hemangioma
Puerto Rico (University of Puerto Rico) - Cavernous hemangioma
Tennessee, Knoxville - Hemangioma
Texas, Crystal Beach - Hemangioma
Canada (Royal Alexandra Hospital) - Cavernous hemangioma
Canada (Royal Prince Alfred Hospital) - Cavernous hemangioma
Canada (University of Sherbrooke) - Liver hemangioma
Japan, Setagaya-Ku - Hemangioma
Japan (University of Yamanashi) - Cavernous hemangioma

Case 1 - Diagnosis:

Cavernous hemangioma, liver

Case 1 - References:

Adult hepatic cavernous haemangioma with highly elevated alpha-fetoprotein *Hong Kong Med J* 2010; Oct;16(5): p400-2.Han SL; Wu XL, et al.
Traumatic rupture of two giant hepatic hemangiomas--a case report. *J Trauma* 2010; Aug;69(2): p476.Chan WH; Huang HJ, et al.
Contrast enhancement of hepatic hemangiomas on multiphase MDCT: Can we diagnose hepatic hemangiomas by comparing enhancement with blood pool? *AJR Am J Roentgenol* 2010; Aug;195(2): p381-6.Oto A; Kulkarni K, et al.
Hepatic hemangioma presenting atypical radiologic findings: a case report. *Radiat Med* 2005; Aug;23(5): p371-5. Hosokawa A; Maeda T, et al.
Benign and malignant vascular tumors of the liver in adults. *Semin Liver Dis* 2008; Aug;28(3): p302-14. Bioulac-Sage P; Laumonier H, et al.
Image of the month. Kasabach-Merritt syndrome in a giant cavernous liver hemangioma. *Arch Surg* 2007; Apr;142(4): p399-400. McCormack L; Petrowsky H; Clavien PA.

Case No. 2, Accession No. 31923 January 2015

Glendale - Mucinous cystadenoma
Orinda (Kaiser Permenente) - Biliary cystadenoma
San Diego (Naval Medical Center) - Mucinous cystic neoplasm
San Francisco (UCSF) - Biliary cystadenoma
San Jose - Biliary cyst
Torrence (Harbor-UCLA Medical Center) - Mucinous cystic neoplasm
Alabama (Cunningham Pathology) - Endometriosis

Connecticut (Danbury Hospital) - Biliary cystadenoma
Delaware (Armed Forces Medical Examiner System) - Mucinous cystic neoplasm of liver
Illinois (Heartland Regional Medical Center) - Biliary mucinous cystadenoma
Illinois, Oak Brook - Bile duct cyst
Maryland (University of Maryland Medical Center) - Biliary cystadenoma
Maryland (Walter Reed NMMC) - Benign hepatic cyst
North Carolina, Clemmons - Mucinous cystadenoma
Ohio (The University of Toledo Medical Center Residents) - Mucinous cystic neoplasm of liver, low grade
Oregon (Oregon Health Science University Residents) - Mucinous cystic neoplasm, liver
Pennsylvania (Drexel University College of Medicine Residents) - Hepatobiliary cystadenoma
Puerto Rico (University of Puerto Rico) - Benign hepatic cyst/biliary duct cyst/mucinous cystic neoplasm
Tennessee, Knoxville - Hepatobiliary cystadenoma
Texas, Crystal Beach - Cyst with foreign body reaction (to vacolated material possibly silicon)
Canada (Royal Alexandra Hospital) - Hepatobiliary cystadeoma
Canada (Royal Prince Alfred Hospital) - Mucinous cystic neoplasm of liver
Canada (University of Sherbrooke) - Mucinous biliary cystadenoma with mesenchymal stroma "ovarian-like"
Japan, Setagaya-Ku - Cholangial cyst
Japan (University of Yamanashi) - Mucinous cystic neoplasm

Case 2 - Diagnosis:
Hepatobiliary mucinous cystadenoma

Case 2 - References:
Spontaneous rupture of a hepatic cystadenoma and cystadenocarcinoma: report of two cases. *J Hepatobiliary Pancreat Surg* 2005;12(5): p409-14. Lempinen M; Halme L, et al.
Hepatobiliary cystadenoma with mesenchymal stroma--a case report.Indian *J Pathol Microbiol* 2006; Apr;49(2): p291-3. Mohan H; Bal A, et al.
Hepatobiliary cystadenoma: a case report and a review of the literature. *Curr Surg* 2006; Jul-Aug;63(4): p285-9. Carson JG; Huerta S; Butler JA.
Detection of recurrent extrahepatic hepatobiliary cystadenoma by EUS (with video). *Gastrointest Endosc* 2006; Oct;64(4): p658-60. Trummer A; Oldhafer KJ, et al.
Large mucinous biliary cystadenoma with "ovarian-like" stroma: a case report. *World J Gastroenterol* 2006 Jun 21;12(23): p3779-81. Beuran M; Venter MD; Dumitru L.

Case No. 3, Accession No. 31689 January 2015

Glendale - Adenocarcinoma
Orinda (Kaiser Permenente) - Adenocarcinoma, favor cholangiocarcinoma
San Diego (Naval Medical Center) - Adenocarcinoma (cholangiocarcinoma vs. metastatic)
San Francisco (UCSF) - Cholangiocarcinoma
San Jose - Adenocarcinoma, cholangiocarcinoma
Torrence (Harbor-UCLA Medical Center) - Cholangiocarcinoma
Alabama (Cunningham Pathology) - Cholangiocarcinoma
Connecticut (Danbury Hospital) - Cholangiocarcinoma
Delaware (Armed Forces Medical Examiner System) - Cholangiocarcinoma
Illinois (Heartland Regional Medical Center) - Adenocarcinoma
Illinois, Oak Brook - Cholangiocarcinoma
Maryland (University of Maryland Medical Center) - Favor cholangiocarcinoma
Maryland (Walter Reed NMMC) - High grade neuroendocrine neoplasm
North Carolina, Clemmons - Metastatic adenocarcinoma, favor colonic origin
Ohio (The University of Toledo Medical Center Residents) - Cholangiocarcinoma
Oregon (Oregon Health Science University Residents) - Cholangiocarcinoma
Pennsylvania (Drexel University College of Medicine Residents) - Cholangiocarcinoma
Puerto Rico (University of Puerto Rico) - Adenocarcinoma vs. cholangiocarcinoma
Tennessee, Knoxville - Cholangiocarcinoma

Texas, Crystal Beach - Cholangiocarcinoma
Canada (Royal Alexandra Hospital) - Metastatic colorectal carcinoma
Canada (Royal Prince Alfred Hospital) - Adenocarcinoma metastatic vs. primary
Canada (University of Sherbrooke) - Metastatic adenocarcinoma to liver from colorectal origin
Japan, Setagaya-Ku - Cholangiocarcinoma
Japan (University of Yamanashi) - Intrahepatic cholangiocellular carcinoma (1); Metastatic adenocarcinoma (1)

Case 3 - Diagnosis:

Cholangiocarcinoma, liver

Case 3 - References:

Pathobiology of biliary epithelia and cholangiocarcinoma: proceedings of the Henry M. and Lillian Stratton Basic Research Single-Topic Conference. *Hepatology* 2008; Dec;48(6): p2040-6. Sirica AE; Nathanson MH, et al.

Surgical outcome and prognostic factors in intrahepatic cholangiocarcinoma. *World J Surg* 2008; Dec;32(12): p2675-80. Nakagohri T; Kinoshita T, et al.

Cholangiocarcinoma: a 7-year experience at a single center in Greece. *World J Gastroenterol* 2008; Oct 28;14(40): p6213-7. Alexopoulou A; Soultati A, et al.

Utility of serum tumor markers, imaging, and biliary cytology for detecting cholangiocarcinoma in primary sclerosing cholangitis. *Hepatology* 2008; Oct;48(4): p1106-17. Charatcharoenwitthaya P; Enders FB, et al.

Mimics of cholangiocarcinoma: spectrum of disease. *Radiographics* 2008; Jul-Aug;28(4): p1115-29. Menias CO; Surabhi VR, et al.

Cholangiocarcinoma: advances in pathogenesis, diagnosis, and treatment. *Gut* 2007; Dec;56(12): p1755-6. Khan SA; Miras A, et al.

Case No. 4, Accession No. 31793 January 2015

Glendale - Solid pseudopapillary tumor of pancreas
Orinda (Kaiser Permenente) - Solid pseudopapillary tumor of pancreas
San Diego (Naval Medical Center) - Solid pseudopapillary neoplasm
San Francisco (UCSF) - Solid pseudopapillary neoplasm
San Jose - Solid pseudopapillary tumor
Torrence (Harbor-UCLA Medical Center) - Solid pseudopapillary neoplasm
Alabama (Cunningham Pathology) - PEcoma
Connecticut (Danbury Hospital) - Solid papillary tumor, pancreas
Delaware (Armed Forces Medical Examiner System) - Solid pseudopapillary tumor
Illinois (Heartland Regional Medical Center) - Solid pseudopapillary neoplasm
Illinois, Oak Brook - Solid pseudopapillary neoplasm
Maryland (University of Maryland Medical Center) - Solid pseudopapillary tumor
Maryland (Walter Reed NMMC) - Solid pseudopapillary neoplasm
North Carolina, Clemmons - Solid pseudopapillary neoplasm
Ohio (The University of Toledo Medical Center Residents) - Solid pseudopapillary tumor
Oregon (Oregon Health Science University Residents) - Solid pseudopapillary tumor
Pennsylvania (Drexel University College of Medicine Residents) - Solid pseudopapillary tumor
Puerto Rico (University of Puerto Rico) - Solid pseudopapillary tumor of pancreas
Tennessee, Knoxville - Solid cystic pseudopapillary tumor
Texas, Crystal Beach - Islet cell tumor (adenoma probable)
Canada (Royal Alexandra Hospital) - Solid pseudopapillary tumor
Canada (Royal Prince Alfred Hospital) - Solid pseudopapillary neoplasm
Canada (University of Sherbrooke) - Solid pseudopapillar neoplasm of pancreas
Japan, Setagaya-Ku - Solid pseudopapillary neoplasm
Japan (University of Yamanashi) - Solid-pseudopapillary neoplasm

Case 4 - Diagnosis:

Solid pseudopapillary neoplasm, pancreas

Case 4 - References:
Acinar cell carcinoma versus solid pseudopapillary tumor of the pancreas in children: a comparison of two rare and overlapping entities with review of the literature. *Pediatr Dev Pathol* 2008; Sep-Oct;11(5): p384-90. Tapia B; Ahrens W, et al.
Aggressive behaviour of solid-pseudopapillary tumor of the pancreas in adults: a case report and review of the literature. *World J Gastroenterol* 2008; Feb 14;14(6): p960-5. Sperti C; Berselli M, et al.
Diagnosis and surgical treatment of solid pseudopapillary neoplasm of the pancreas: analysis of 24 cases. *Can J Surg* 2011; Dec;54(6): p368-74. Guo N; Zhou QB, et al.
Solid pseudopapillary neoplasm of the pancreas: a rare and atypically aggressive disease among male patients. *Am Surg* 2010; Oct;76(10): p1075-8. Lin MY; Stabile BE.
Solid-pseudopapillary neoplasm: a pancreatic enigma. *Arch Pathol Lab Med* 2009; Dec;133(12): p1989-93. Chakhachiro ZI; Zaatari G.
Solid pseudopapillary neoplasms of the pancreas: a multi-institutional study of 21 patients. *J Surg Res* 2009; Nov;157(1): pe137-42. Matos JM; Grutzmann R, et al.

Case No. 5, Accession No. 29986 January 2015

Glendale - Mucinous cystic neoplasm
Orinda (Kaiser Permenente) - Mucinous cystic neoplasm
San Diego (Naval Medical Center) - Mucinous cystic neoplasm
San Francisco (UCSF) - Mucinous cystic neoplasm
San Jose - Numerous cystic neoplasm
Torrence (Harbor-UCLA Medical Center) - Mucinous cystic neoplasm
Alabama (Cunningham Pathology) - Mucinous cystic neoplasm
Connecticut (Danbury Hospital) - Mucinous cystadenoma
Delaware (Armed Forces Medical Examiner System) - Mucinous cystic neoplasm of pancreas with moderate dysplasia
Illinois (Heartland Regional Medical Center) - Mucinous cystic neoplasm with moderate dysplasia
Illinois, Oak Brook - Mucinous cystic neoplasm with LGD
Maryland (University of Maryland Medical Center) - Mucinous cystic neoplasm
Maryland (Walter Reed NMMC) - Mucinous cystic neoplasm
North Carolina, Clemmons - Mucinous cystic neoplasm with intermediate grade dysplasia
Ohio (The University of Toledo Medical Center Residents) - Mucinous cystic neoplasm of pancreas, intermediate dysplasia
Oregon (Oregon Health Science University Residents) - Mucinous cystic neoplasm, pancreas
Pennsylvania (Drexel University College of Medicine Residents) - Mucinous cystic neoplasm with low grade dysplasia
Puerto Rico (University of Puerto Rico) - Mucinous cystic neoplasm
Tennessee, Knoxville - Mucinous cystic neoplasm
Texas, Crystal Beach - Mucinous cystic tumor (adenoma)
Canada (Royal Alexandra Hospital) - Mucinous cystic neoplasm with low grade dysplasia
Canada (Royal Prince Alfred Hospital) - Mucinous cystic neoplasm of pancreas
Canada (University of Sherbrooke) - Mucinous cystadenoma of the pancreas
Japan, Setagaya-Ku - Mucinous cystadenoma
Japan (University of Yamanashi) - Mucinous cystic neoplasm

Case 5 - Diagnosis:
Mucinous cystic neoplasm of pancreas with moderate dysplasia

Case 5 - References:
Mucinous nonneoplastic cyst of the pancreas: apomucin phenotype distinguishes this entity from intraductal papillary mucinous neoplasm. *Hum Pathol* 2010; Apr;41(4): p513-21. Cao W; Adley BP, et al.
Clinical implications of mucinous nonneoplastic cysts of the pancreas. *Pancreas* 2012; Apr;41(3): p441-6. Nadig SN; Pedrosa I, et al.

Pseudocyst of the pancreas: the role of cytology and special stains for mucin. *Cancer* 2009; Apr 25;117(2): p101-7. Gonzalez Obeso E; Murphy E, et al.
Cyst fluid carcinoembryonic antigen is an accurate diagnostic marker of pancreatic mucinous cysts. *Pancreas* 2011; Oct;40(7): p1024-8. Cizginer S; Turner BG, et al.
Pancreatic cysts: pathologic classification, differential diagnosis, and clinical implications. *Arch Pathol Lab Med* 2009; Mar;133(3): p423-38. Basturk O; Coban I; Adsay NV.
Pancreatic cyst aspiration analysis for cystic neoplasms: mucin or carcinoembryonic antigen--which is better? *Surgery* 2010; Oct;148(4): p638-44; discussion 644-5.Morris-Stiff G; Lentz G, et al.

Case No. 6, Accession No. 31651 **January 2015**

Glendale - High grade leiomyosarcoma
Orinda (Kaiser Permenente) - Epithelioid leiomyosarcoma
San Diego (Naval Medical Center) - Leiomyosarcoma
San Francisco (UCSF) - Leiomyosarcoma
San Jose - Leiomyosarcoma
Torrence (Harbor-UCLA Medical Center) - Metastatic leiomyosarcoma
Alabama (Cunningham Pathology) - Leiomyosarcoma
Connecticut (Danbury Hospital) - Leiomyosarcoma
Delaware (Armed Forces Medical Examiner System) - Leiomyosarcoma
Illinois (Heartland Regional Medical Center) - Leiomyosarcoma
Illinois, Oak Brook - Leiomyosarcoma
Maryland (University of Maryland Medical Center) - Leiomyosarcoma
Maryland (Walter Reed NMMC) - Leiomyosarcoma
North Carolina, Clemmons - Leiomyosarcoma
Ohio (The University of Toledo Medical Center Residents) - Leiomyosarcoma
Oregon (Oregon Health Science University Residents) - Leiomyosarcoma
Pennsylvania (Drexel University College of Medicine Residents) - Leiomyosarcoma
Puerto Rico (University of Puerto Rico) - Leiomyosarcoma
Tennessee, Knoxville - Leiomyosarcoma
Texas, Crystal Beach - Leiomyosarcoma
Canada (Royal Alexandra Hospital) - Leiomyosarcoma
Canada (Royal Prince Alfred Hospital) - Leiomyosarcoma
Canada (University of Sherbrooke) - Leiomyosarcoma
Japan, Setagaya-Ku - Leiomyosarcoma
Japan (University of Yamanashi) - Leiomyosarcoma

Case 6 - Diagnosis:
Leiomyosarcoma, small intestine

Case 6 - References:
Primary small bowel malignancy: a 10-year clinical experience from Southern Taiwan. *Hepatogastroenterology* 2013; Jun;60(124): p756-8. Lin CY; Chuah SK, et al.
Primary malignant diseases of the small intestine. *AJR Am J Roentgenol* 2011; Jul;201(1): pW9-14. McLaughlin PD; Maher MM.
Leiomyosarcoma of the colon: unresolved issues of a rare but highly aggressive malignancy. *Am Surg* 2011; Apr;77(4): pE62-4. Resch T; Oberhuber R, et al.
True smooth muscle tumors of the small intestine: a clinicopathologic, immunhistochemical, and molecular genetic study of 25 cases. *Am J Surg Pathol* 2009; Mar;33(3): p430-6. Miettinen M; Sobin LH; Lasota J.
Periampullary leiomyosarcoma presenting with cutaneous metastases: a rare entity. *South Med J* 2010; Nov;103(11): p1190-1. Pahwa M; Girotra M, et al.

Case No. 7, Accession No. 31690 January 2015

Glendale - Mucinous adenocarcinoma
Orinda (Kaiser Permenente) - Mucinous carcinoma
San Diego (Naval Medical Center) - Adenocarcinoma with signet cell carcinoma
San Francisco (UCSF) - Mucinous carcinoma with signet ring cell features
San Jose - Signet ring adenocarcinoma
Torrence (Harbor-UCLA Medical Center) - Mucinous adenocarcinoma
Alabama (Cunningham Pathology) - Adenocarcinoma
Connecticut (Danbury Hospital) - Signet ring carcinoma
Delaware (Armed Forces Medical Examiner System) - Signet ring cell carcinoma
Illinois (Heartland Regional Medical Center) - Adenocarcinoma and cholecystitis
Illinois, Oak Brook - Signet ring cell adenocarcinoma
Maryland (University of Maryland Medical Center) - Mucinous adenocarcinoma
Maryland (Walter Reed NMMC) - Adenocarcinoma with signet ring features
North Carolina, Clemmons - Adenocarcinoma, signet ring cell pattern (rule out metastasis from other site)
Ohio (The University of Toledo Medical Center Residents) - Mucinous adenocarcinoma of gallbladder with signet ring features
Oregon (Oregon Health Science University Residents) - Adenocarcinoma, gallbladder
Pennsylvania (Drexel University College of Medicine Residents) - Gallbladder adenocarcinoma
Puerto Rico (University of Puerto Rico) - Mixed mucinous-signet ring cell carcinoma
Tennessee, Knoxville - Mucinous adenocarcinoma
Texas, Crystal Beach - Mucinous adenocarcinoma
Canada (Royal Alexandra Hospital) - Adenocarcinoma with mucinous features
Canada (Royal Prince Alfred Hospital) - High grade adenocarcinoma with signet ring morphology, xanthogranulomatous cholecystitis
Canada (University of Sherbrooke) - Metastasis to the gallbladder of a mucinous (colloid) carcinoma of colorectal origin
Japan, Setagaya-Ku - Mucinous adenocarcinoma
Japan (University of Yamanashi) - Mucinous carcinoma (1); Signet-ring cell carcinoma (1)

Case 7 - Diagnosis:
Mucinous adenocarcinoma with signet ring cell features, gallbladder

Case 7 - References:
Mucinous carcinomas of the gallbladder: clinicopathologic analysis of 15 cases identified in 606 carcinomas. *Arch Pathol Lab Med* 2012; Nov;136(11): p1347-58. Dursun N; Escalona OT, et al.
Nonneoplastic signet-ring cell change in gastrointestinal and biliary tracts: a pitfall for overdiagnosis. *Ann Diagn Pathol* 2011; Dec;15(6): p490-6. Dhingra S; Wang H.
Primary signet ring cell carcinoma of gall bladder: report of an extremely rare histological type of primary gallbladder carcinoma. *BMJ Case Rep* 2010; 2010 p. Ahmad Z; Qureshi A.
Signet ring cell carcinoma of the gallbladder in a 22-year-old man: a case report and review of the literature. *Int J Surg Pathol* 2010; Oct;18(5): p358-62. Czyszczon IA; Alatassi H.
Signet ring cell carcinoma of gallbladder with celiac lymph node metastasis in a young man. *J Cancer Res Ther* 2010; Jul-Sep;6(3): p379-81. Mondal SK.

Case No. 8, Accession No. 31858 January 2015

Glendale - Acquired cystic kidney disease
Orinda (Kaiser Permenente) - Autosomal dominant polycystic kidney disease
San Diego (Naval Medical Center) - Acquired polycystic cystic kidney disease
San Francisco (UCSF) - Acquired renal cystic disease
San Jose - Polycystic kidney disease
Torrence (Harbor-UCLA Medical Center) - Autosomal dominant polycystic kidney disease
Alabama (Cunningham Pathology) - Polycystic kidney disease

Connecticut (Danbury Hospital) - Adult polycystic kidney disease
Delaware (Armed Forces Medical Examiner System) - Adult polycystic kidney disease
Illinois (Heartland Regional Medical Center) - Autosomal dominant polycystic disease of kidneys
Illinois, Oak Brook - Autosomal dominant polycystic kidney disease
Maryland (University of Maryland Medical Center) - Acquired polycystic kidney disease
Maryland (Walter Reed NMMC) - Acquired renal cystic disease
North Carolina, Clemmons - Adult polycystic kidney disease with focal papillary oncocytic hyperplasia
Ohio (The University of Toledo Medical Center Residents) - Renal cell carcinoma arising from autosomal dominant polycystic kidney disease
Oregon (Oregon Health Science University Residents) - Papillary adenoma, polycystic kidney disease
Pennsylvania (Drexel University College of Medicine Residents) - Adult polycystic kidney disease
Puerto Rico (University of Puerto Rico) - Polycystic kidney disease, autosomal dominant vs. acquired
Tennessee, Knoxville - Adult polycystic kidney disease
Texas, Crystal Beach - Polycystic kidney with intracystic papillomatosis
Canada (Royal Alexandra Hospital) - Polycystic kidney disease
Canada (Royal Prince Alfred Hospital) - Adult polycystic kidney disease
Canada (University of Sherbrooke) - Acquired cystic kidney disease
Japan, Setagaya-Ku - Cystic nephroma
Japan (University of Yamanashi) - Autosomal dominant polycystic kidney disease

Case 8 - Diagnosis:

Adult polycystic kidney disease

Case 8 - References:

Blunt renal trauma in adult polycystic kidney disease and the use of nephron sparing selective arterial embolization. *J Trauma* 2009; Feb;66(2): p564-6. Reay EK; McEleny K, et al.
Autosomal dominant polycystic kidney disease: recent advances in pathogenesis and potential therapies. *Clin Exp Nephrol* 2013; Jun;17(3): p317-26. Mochizuki T; Tsuchiya K; Nitta K.
Localized cystic disease of the kidney: distinction from cystic neoplasms and hereditary polycystic diseases. *Am J Surg Pathol* 2013; Apr;37(4): p506-13. Ding Y; Chen L, et al.
Adult renal cystic disease: a genetic, biological, and developmental primer. *Radiographics* 2010; Oct;30(6): p1509-23. Katabathina VS; Kota G, et al.
Polycystic kidney disease. *Annu Rev Med* 2009;;60:321-37. Harris PC; Torres VE.

Case No. 9, Accession No. 31801 January 2015

Glendale - Angiomyolipoma
Orinda (Kaiser Permenente) - Angiomyolipoma
San Diego (Naval Medical Center) - Angiomyolipoma
San Francisco (UCSF) - Angiomyolipoma
San Jose - Angiomyolipoma
Torrence (Harbor-UCLA Medical Center) - Angiomyolipoma
Alabama (Cunningham Pathology) - Angiomyolipoma
Connecticut (Danbury Hospital) - Epithelioid angiomyolipoma
Delaware (Armed Forces Medical Examiner System) - Angiomyolipoma
Illinois (Heartland Regional Medical Center) - Angiomyolipoma
Illinois, Oak Brook - Sarcomatoid renal cell carcinoma
Maryland (University of Maryland Medical Center) - Angiomyolipoma
Maryland (Walter Reed NMMC) - Angiomyolipoma
North Carolina, Clemmons - Epithelioid angiomyolipoma
Ohio (The University of Toledo Medical Center Residents) - Angiomyolipoma
Oregon (Oregon Health Science University Residents) - Angiomyolipoma
Pennsylvania (Drexel University College of Medicine Residents) - Angiomyolipoma
Puerto Rico (University of Puerto Rico) - Angiomyolipoma
Tennessee, Knoxville - Angiomyolipoma

Texas, Crystal Beach - Spindly carcinoma
Canada (Royal Alexandra Hospital) - Angiomyolipoma
Canada (Royal Prince Alfred Hospital) - Angiomyolipoma
Canada (University of Sherbrooke) - Angiomyolipoma
Japan, Setagaya-Ku - Angiomyolipoma
Japan (University of Yamanashi) - Angiomyolipoma

Case 9 - Diagnosis:
Angiomyolipoma, kidney

Case 9 - References:

Are there useful CT features to differentiate renal cell carcinoma from lipid-poor renal angiomyolipoma? *AJR Am J Roentgenol* 2013; Nov;201(5): p1017-28. Yang CW; Shen SH, et al.
Minimal fat angiomyolipoma: a controversial subtype of classic angiomyolipoma. *AJR Am J Roentgenol* 2013; Aug;201(2): pW359. Pusiol T; Piscioli I; Scialpi M.
Patterns of renal angiomyolipoma regression post embolisation on medium- to long-term follow-up. *Br J Radiol* 2013; Apr;86(1024): p20120633. Patatas K; Robinson GJ, et al.
Fat-poor angiomyolipoma and renal cell carcinoma: differentiation with MR imaging and accuracy of histopathologic evaluation. *Radiology* 2012; Dec;265(3): p979-80; author reply 980-1. Cardone G; D'Andrea A, et al.
Giant adrenal angiomyolipoma. *J Clin Endocrinol Metab* 2012; Nov;97(11): p3835-6. Hu H; Xi X.
Expression of E-cadherin in angiomyolipoma. *Hum Pathol* 2012; Dec;43(12): p2348-53. Wang Z; Gong Q; Fan Q.

Case No. 10, Accession No. 31700 January 2015

Glendale - High-grade, invasive urothelial carcinoma
Orinda (Kaiser Permenente) - Invasive high grade urothelial carcinoma
San Diego (Naval Medical Center) - Urothelial carcinoma
San Francisco (UCSF) - High grade papillary urothelial carcinoma, invasive into muscularis propria
San Jose - High grade, TCC
Torrence (Harbor-UCLA Medical Center) - High grade urothelial cell carcinoma consistent with small cell component
Alabama (Cunningham Pathology) - Urothelial carcinoma
Connecticut (Danbury Hospital) - High grade papillary urothelial carcinoma, high grade
Delaware (Armed Forces Medical Examiner System) - Invasive high grade urothelial carcinoma
Illinois (Heartland Regional Medical Center) - Invasive high grade urothelial carcinoma
Illinois, Oak Brook - Invasive urothelial carcinoma, high grade
Maryland (University of Maryland Medical Center) - Myoinvasive papillary urothelial carcinoma
Maryland (Walter Reed NMMC) - High grade urothelial carcinoma
North Carolina, Clemmons - Papillary urothelial carcinoma, high grade, invasive
Ohio (The University of Toledo Medical Center Residents) - Invasive urothelial cell carcinoma, high grade
Oregon (Oregon Health Science University Residents) - High grade urothelial carcinoma with endophytic growth
Pennsylvania (Drexel University College of Medicine Residents) - Invasive high grade urothelial carcinoma
Puerto Rico (University of Puerto Rico) - Infiltrating urothelial carcinoma, high grade
Tennessee, Knoxville - Invasive high grade urothelial carcinoma
Texas, Crystal Beach - Transitional cell carcinoma
Canada (Royal Alexandra Hospital) - Invasive high grade urothelial carcinoma
Canada (Royal Prince Alfred Hospital) - High grade invasive papillary urothelial carcinoma
Canada (University of Sherbrooke) - Urothelial carcinoma-invasive
Japan, Setagaya-Ku - Urothelial carcinoma
Japan (University of Yamanashi) - Invasive urothelial carcinoma, high grade

Case 10 - Diagnosis:
High grade invasive papillary urothelial carcinoma, bladder

Case 10 - References:

Urothelial dysplasia of the bladder: diagnostic features and clinical significance. *Anal Quant Cytol Histol* 2013; Jun;35(3): p121-9. Lopez-Beltran A; Montironi R, et al.

Malignant glandular lesions and glandular differentiation in invasive/noninvasive urothelial carcinoma of the urinary bladder. *Ann Diagn Pathol* 2011; Dec;15(6): p422-6. Behzatoglu K.

Histologic grading of urothelial carcinoma: a reappraisal. *Hum Pathol* 2012; Dec;43(12): p2097-108. Cheng L; MacLennan GT; Lopez-Beltran A.

Urothelial carcinoma with villoglandular differentiation: a study of 14 cases. *Mod Pathol* 2009; Oct;22(10): p1280-6. Lim M; Adsay NV; Grignon D, et al.

High-grade papillary urothelial carcinoma of the urinary tract: a clinicopathologic analysis of a post-World Health Organization/International Society of Urological Pathology classification cohort from a single academic center. *Hum Pathol* 2012; Jan;43(1): p115-20. Chaux A; Karram S, et al.